A 29-year-old previously healthy man comes to the hospital with a right leg injury after a cycling accident. He reports pain in the lower leg and inability to bear weight. X-ray reveals right tibial and fibular shaft fractures. The patient undergoes closed reduction and immobilization of the fractures. Several hours later, he has increasingly severe pain in his right leg. Physical examination shows increased tension within the anterior compartment. Which of the following structures is most likely to be compromised by this patient's acute complication?

A. Deep peroneal nerve
B. Great saphenous vein
C. Peroneal veins
D. Posterior tibial artery
E. Superficial peroneal nerve
F. Tibial nerve

Submit

A 29-year-old previously healthy man comes to the hospital with a right leg injury after a cycling accident. He reports pain in the lower leg and inability to bear weight. X-ray reveals right tibial and fibular shaft fractures. The patient undergoes closed reduction and immobilization of the fractures. Several hours later, he has increasingly severe pain in his right leg. Physical examination shows increased tension within the anterior compartment. Which of the following structures is most likely to be compromised by this patient's acute complication?

- ✓ A. Deep peroneal nerve (40%)
- B. Great saphenous vein (6%)
- C. Peroneal veins (7%)
- D. Posterior tibial artery (6%)
- E. Superficial peroneal nerve (24%)
- F. Tibial nerve (14%)

Omitted
Correct answer
A

40%
Answered correctly

13 secs
Time Spent

03/03/2020
Last Updated

Explanation

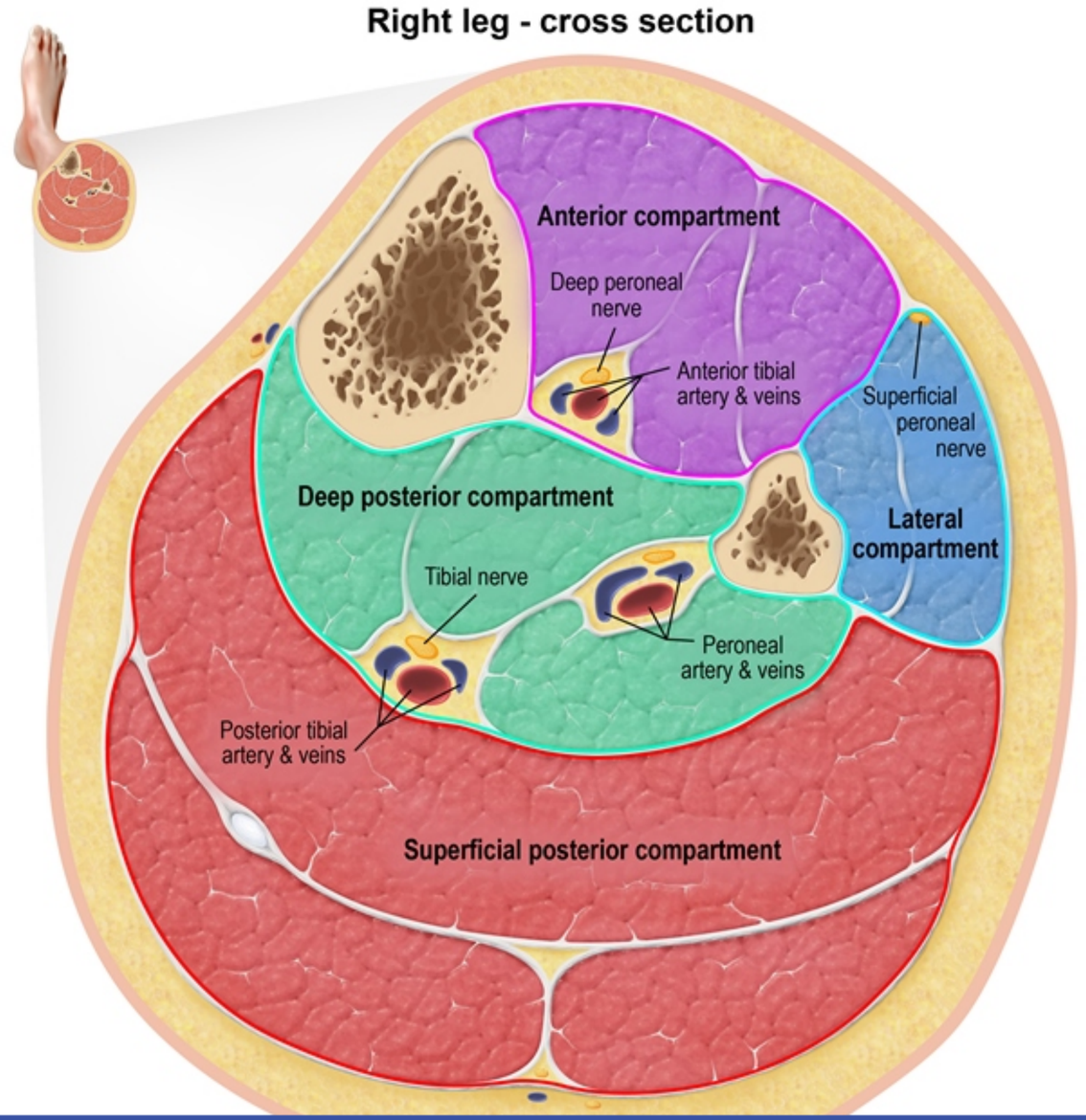
Right leg - cross section
Anterior compartment
Deep peroneal nerve
Anterior tibial artery & veins
Superficial peroneal nerve
Deep posterior compartment
Lateral compartment
Tibial nerve
Peroneal artery & veins
Posterior tibial artery & veins
Superficial posterior compartment

The deep fascia of the leg, the fascial intermuscular septae, and the interosseous membrane divide the leg into 4 compartments (anterior, lateral, and superficial and deep posterior). The fascia is inelastic and limits outward expansion of the contracting muscles. If the pressure in a compartment increases, the circulation within it can become compromised, leading to severe pain and eventual tissue ischemia. This complication, **acute compartment syndrome** (ACS), can be due to long-bone fractures, crush injury, thermal injury, or nontraumatic causes (eg, bleeding disorders, vascular disease). Early diagnosis and surgical decompression (fasciotomy) of the involved compartments are necessary to prevent permanent and disabling injury (eg, myonecrosis, nerve damage, amputation).

The most common site for ACS is the **anterior compartment** of the leg, which includes the foot extensor muscles, **anterior tibial artery**, and the **deep peroneal (fibular) nerve**. Injury to the deep peroneal nerve causes decreased sensation between the first and second toes, decreased dorsiflexion of the foot, foot drop, and claw foot.

**(Choice B)** The great (long) saphenous vein starts in the dorsum of the foot and runs along the medial leg and anterior thigh before merging with the common femoral vein in the femoral triangle. It is outside the deep fascia and is not vulnerable to ACS.

**(Choice C)** The peroneal veins accompany the peroneal artery and drain blood from the lateral compartment into the deep posterior compartment and eventually into the posterior tibial veins.

**(Choices D and F)** The deep posterior compartment contains the posterior tibial artery, peroneal artery, and tibial nerve. ACS involving this compartment may cause decreased sensation in the plantar surface, decreased toe flexion, and pain with passive toe extension.

**(Choice E)** The lateral compartment of the leg contains the superficial peroneal nerve and the proximal part of the deep peroneal nerve. ACS in this compartment can produce loss of sensation in the lower leg and dorsum of the foot as well as foot drop.

**Educational objective:**
Acute compartment syndrome (ACS) is caused by increased pressure within fascial compartments of the limbs, leading to impaired perfusion. ACS can cause severe pain, myonecrosis, and nerve injury. The anterior compartment of the leg, which contains the deep peroneal (fibular) nerve, is the most common site of ACS.

**References**

- Acute lower-leg compartment syndrome.

A 56-year-old previously healthy man comes to the office due to decreased hearing in both ears. He reports difficulty understanding conversations in crowded rooms. His wife adds that they often argue about the volume of the television set. The patient cannot remember precisely when he first noticed hearing loss but says it has been present at least 6 months and is getting worse. For the past 12 years, he has worked in a factory where he has to shout to communicate with coworkers and has seldom worn hearing protection. An audiogram is obtained as shown in the image below.

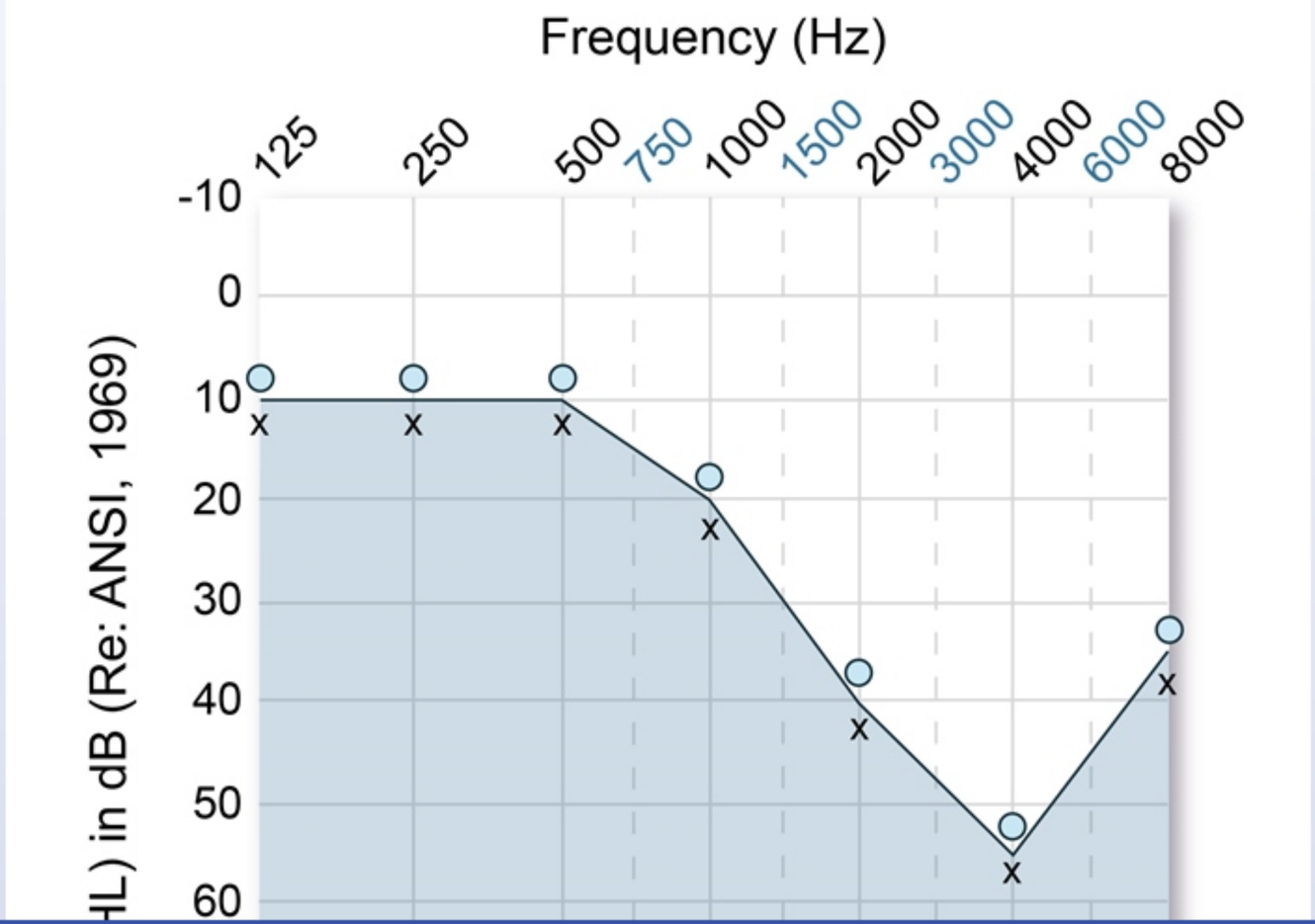

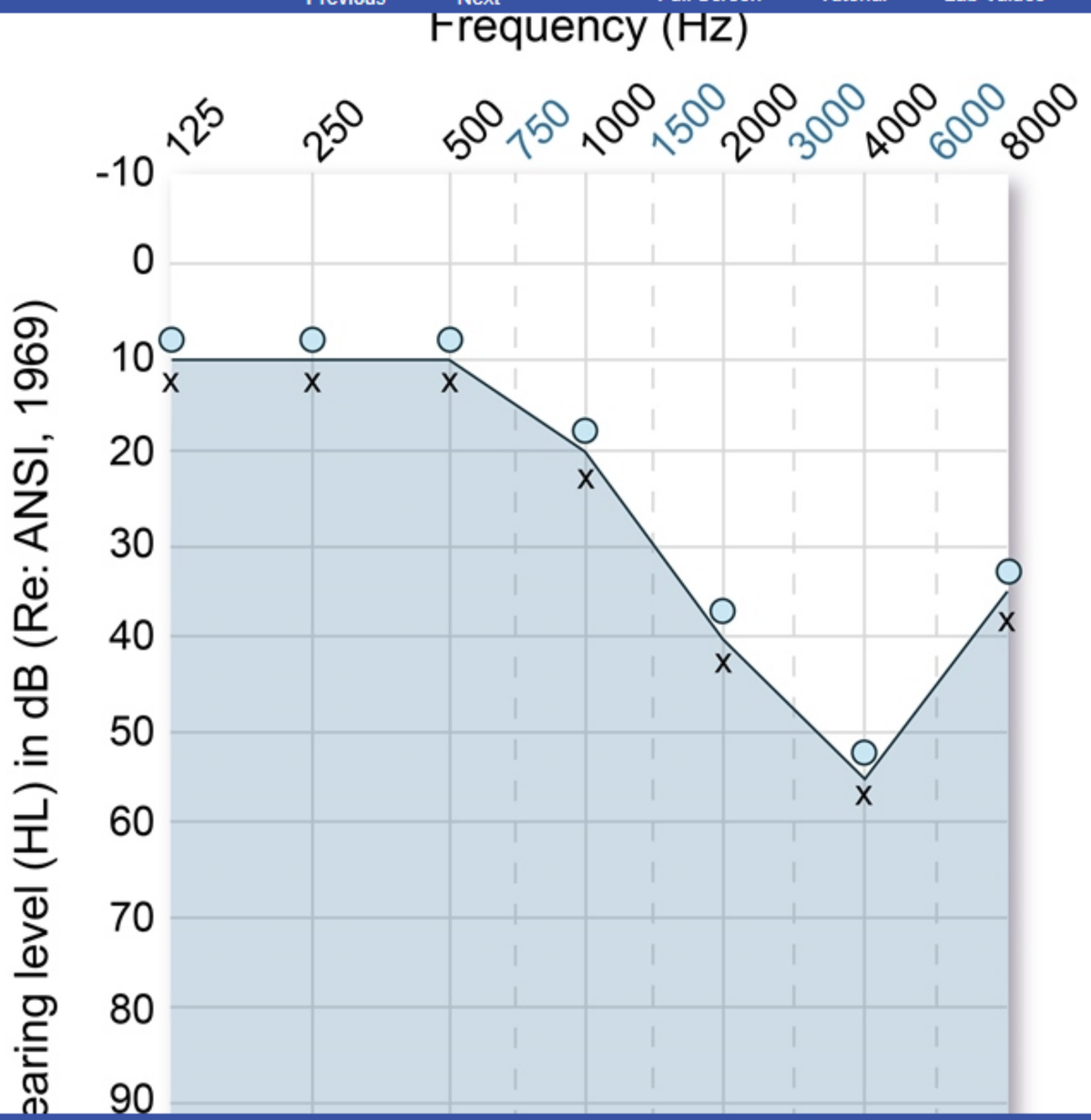
Frequency (Hz)
125
250
500
750
1000
1500
2000
3000
4000
6000
8000
-10
0
10
20
30
40
50
60
70
80
90
earing level (HL) in dB (Re: ANSI, 1969)

Frequency (Hz)

Exhibit Display

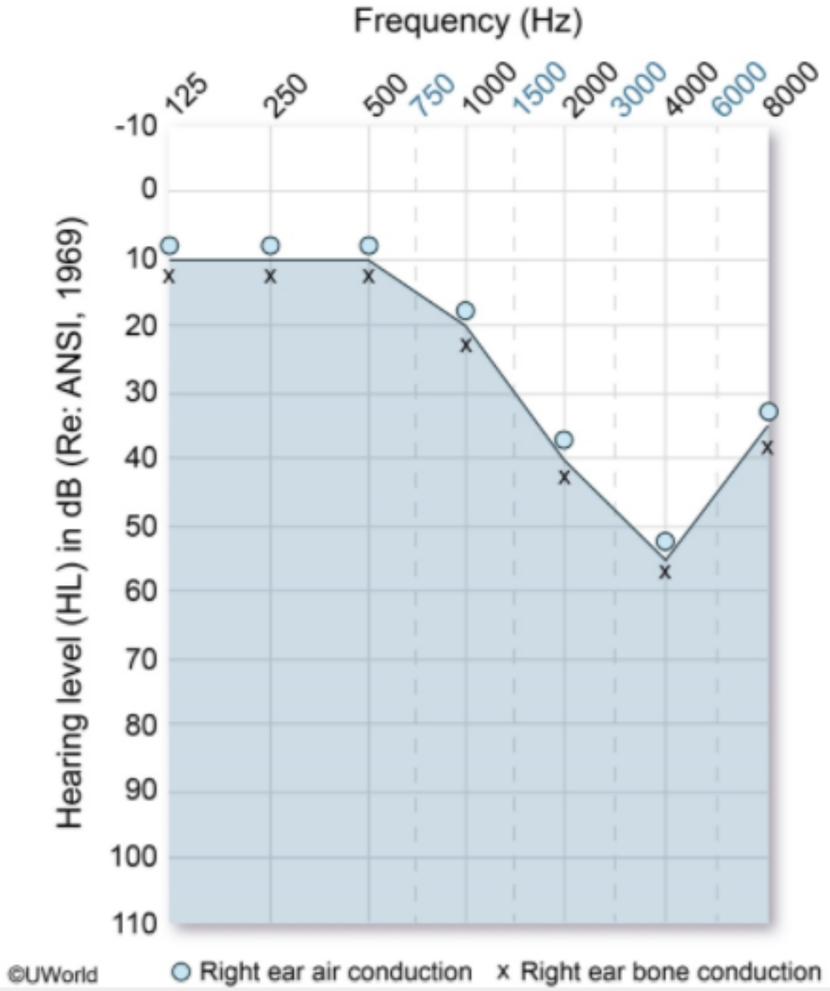


Zoom In | Zoom Out | Reset | Add To New Card | Existing Card

90

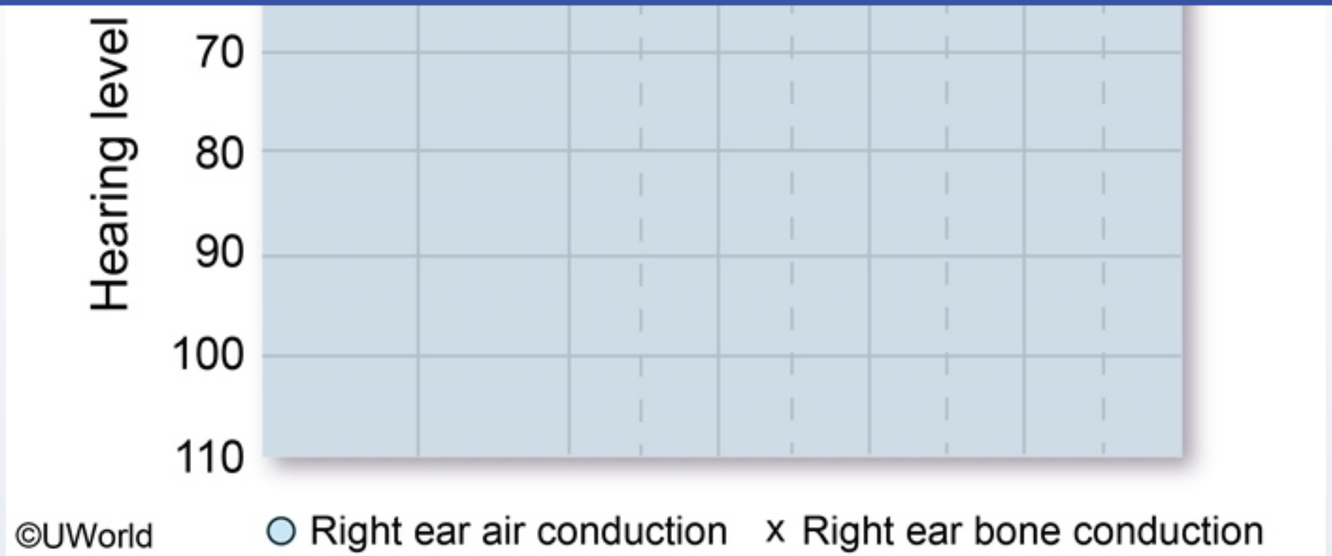


Which of the following is most likely abnormal in this patient?

- A. Auditory nerve
- B. Cochlear cupula
- C. Middle ear ossicles
- D. Organ of Corti
- E. Round window
- F. Tympanic membrane

Submit

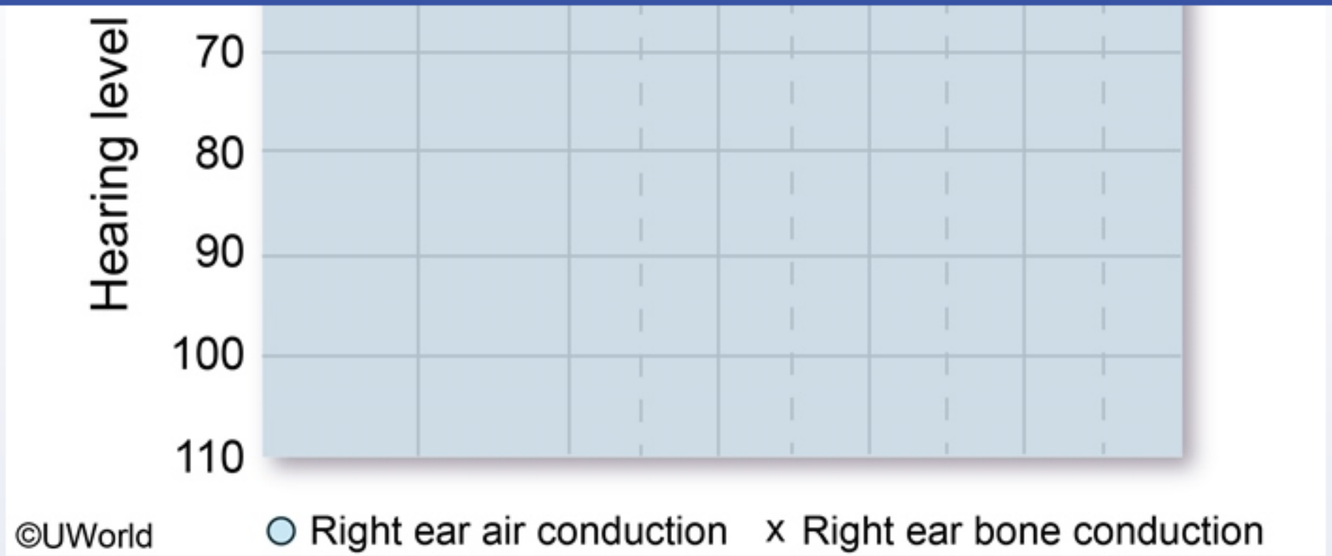


Which of the following is most likely abnormal in this patient?

- A. Auditory nerve (10%)
- B. Cochlear cupula (13%)
- C. Middle ear ossicles (13%)
- ✓ D. Organ of Corti (51%)
- E. Round window (2%)
- F. Tympanic membrane (8%)

Omitted
Correct answer

51%
Answered correctly

09 secs
Time Spent

01/23/2020
Last Updated

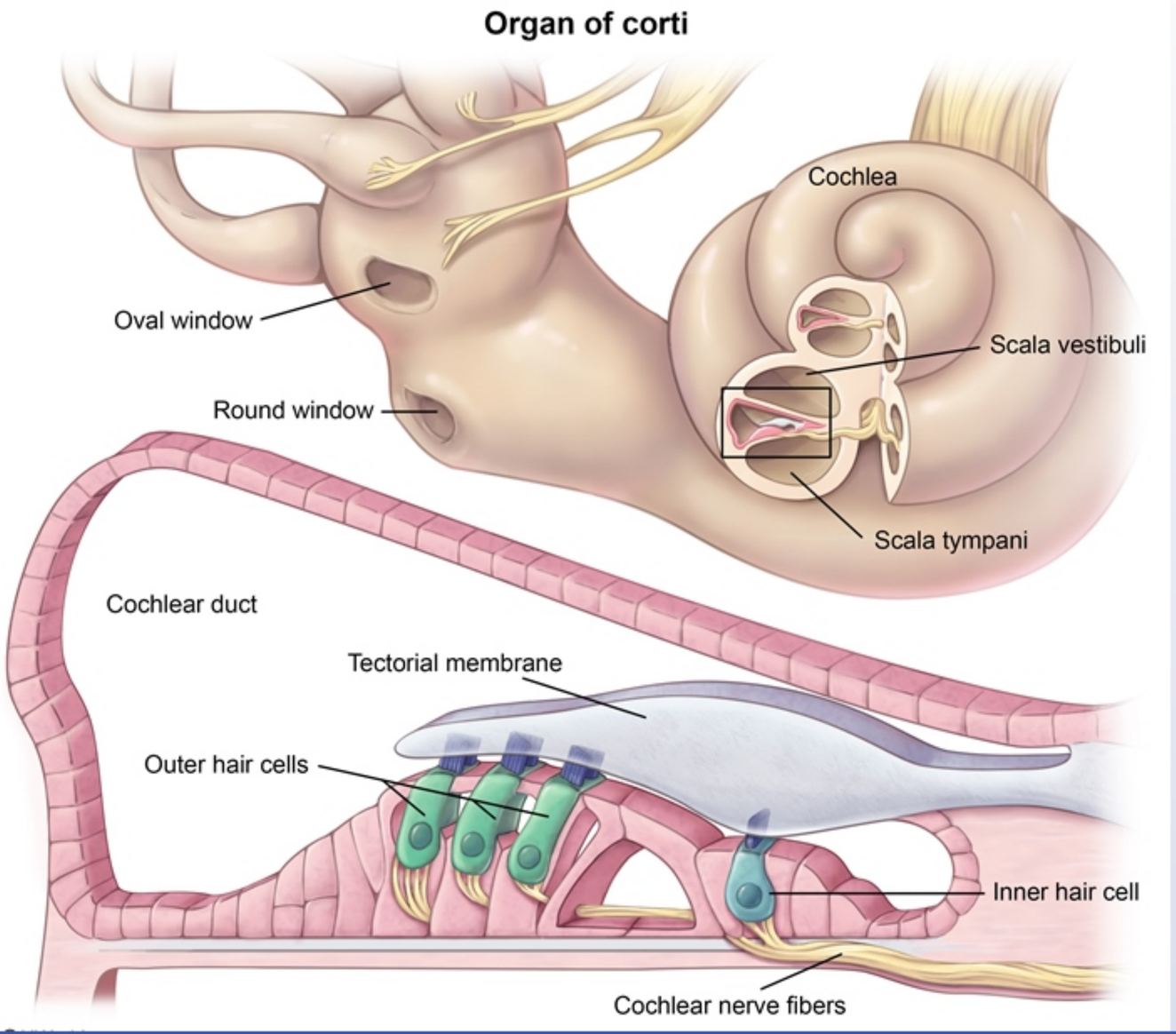
Organ of corti
Cochlea
Oval window
Scala vestibuli
Round window
Scala tympani
Cochlear duct
Tectorial membrane
Outer hair cells
Inner hair cell
Cochlear nerve fibers

©UWorld

This patient has high-frequency hearing loss due to chronic noise exposure. Transduction of mechanical sound waves into nerve impulses occurs in the **organ of Corti** through the following steps:

1. Sound reaches the middle ear by vibrating the tympanic membrane.
2. The vibration is transferred to the oval window by the ossicles.
3. Vibration of the oval window causes vibration of the basilar membrane, which in turn causes bending of the hair cell cilia against the tectorial membrane.
4. Hair cell bending causes oscillating hyperpolarization and depolarization of the auditory nerve, thereby creating nerve impulses from sound.

**Noise-induced hearing loss** results from trauma to the **stereociliated hair cells** of the organ of Corti. The acoustic reflex normally dampens the effects of loud noise by causing the stapedius and tensor tympani muscles to contract, which lessens the responsiveness of the ossicles to sound. However, prolonged noise exposure can cause distortion or fracture of the stereocilia due to shearing forces against the tectorial membrane. High-frequency hearing is lost first, regardless of the frequency of the sound causing the damage.

**(Choice A)** Hearing loss originating in the auditory nerve is most commonly due to a vestibular schwannoma (acoustic neuroma). Patients develop high-frequency sensorineural hearing loss, but symptoms are usually unilateral.

**(Choice B)** The cochlear cupula is the apex of the cochlea and is distant from the oval window. The distal cochlea primarily registers low-frequency sound.

**(Choice C)** Defects of the middle ear ossicles (eg, otosclerosis) can cause hearing loss that generally affects air conduction across all frequencies. This patient's hearing loss affects both air and bone conduction.

**(Choice E)** The round window lies between the middle and inner ear and moves outward when the stapes causes the oval window to move inward. Malformation of the round window can cause congenital hearing impairment, but acquired disorders are rare.

**(Choice F)** Perforation or rupture of the tympanic membrane can occur with infection, trauma, pressure changes, or sudden and very loud noises. Rupture of the tympanic membrane causes unilateral conductive hearing loss.

**Educational objective:**
Prolonged exposure to loud noises causes hearing loss due to damage to the stereociliated hair cells of the organ of Corti.

4. Hair cell bending causes oscillating hyperpolarization and depolarization of the auditory nerve, thereby creating nerve impulses from sound.

**Noise-induced hearing loss** results from trauma to the **stereociliated hair cells** of the organ of Corti. The acoustic reflex normally dampens the effects of loud noise by causing the stapedius and tensor tympani muscles to contract, which lessens the responsiveness of the ossicles to sound. However, prolonged noise exposure can cause distortion or fracture of the stereocilia due to shearing forces against the tectorial membrane. High-frequency hearing is lost first, regardless of the frequency of the sound causing the damage.

**(Choice A)** Hearing loss originating in the auditory nerve is most commonly due to a vestibular schwannoma (acoustic neuroma). Patients develop high-frequency sensorineural hearing loss, but symptoms are usually unilateral.

**(Choice B)** The cochlear cupula is the apex of the cochlea and is distant from the oval window. The distal cochlea primarily registers low-frequency sound.

**(Choice C)** Defects of the middle ear ossicles (eg, otosclerosis) can cause hearing loss that generally affects air conduction across all frequencies. This patient's hearing loss affects both air and bone conduction.

**(Choice E)** The round window lies between the middle and inner ear and moves outward when the stapes causes the oval window to move inward. Malformation of the round window can cause congenital hearing impairment, but acquired disorders are rare.

**(Choice F)** Perforation or rupture of the tympanic membrane can occur with infection, trauma, pressure changes, or sudden and very loud noises. Rupture of the tympanic membrane causes unilateral conductive hearing loss.

**Educational objective:**
Prolonged exposure to loud noises causes hearing loss due to damage to the stereociliated hair cells of the organ of Corti.

**References**

- Hearing impairments caused by genetic and environmental factors.

| Anatomy | Ear, Nose & Throat (ENT) | Hearing loss |
|---|---|---|
| Subject | System | Topic |

Copyright © UWorld. All rights reserved.

A 6-year-old boy is brought to the emergency department by his parents due to persistent nasal bleeding. The boy picks his nose frequently and has had several nosebleeds in the past, all of which stopped spontaneously after pinching the nose. The parents say that they have been pinching the nasal alae for over 30 minutes while the boy leans forward. Family history is negative for bleeding disorders. The patient takes no medications and has no allergies. Examination shows continuous blood trickle from his right nostril. Silver nitrate cautery is performed and the bleeding stops. Cautery was most likely applied to which of the following locations in this patient's nasal cavity?

A. Inferior turbinate

B. Middle meatus

C. Nasal septum

D. Posterior choanae

E. Posterolateral wall

Submit

A 6-year-old boy is brought to the emergency department by his parents due to persistent nasal bleeding. The boy picks his nose frequently and has had several nosebleeds in the past, all of which stopped spontaneously after pinching the nose. The parents say that they have been pinching the nasal alae for over 30 minutes while the boy leans forward. Family history is negative for bleeding disorders. The patient takes no medications and has no allergies. Examination shows continuous blood trickle from his right nostril. Silver nitrate cautery is performed and the bleeding stops. Cautery was most likely applied to which of the following locations in this patient's nasal cavity?

- A. Inferior turbinate (12%)
- B. Middle meatus (10%)
- ✓ C. Nasal septum (45%)
- D. Posterior choanae (10%)
- E. Posterolateral wall (21%)

Omitted
Correct answer
C

45%
Answered correctly

02 secs
Time Spent

05/16/2020
Last Updated

Explanation

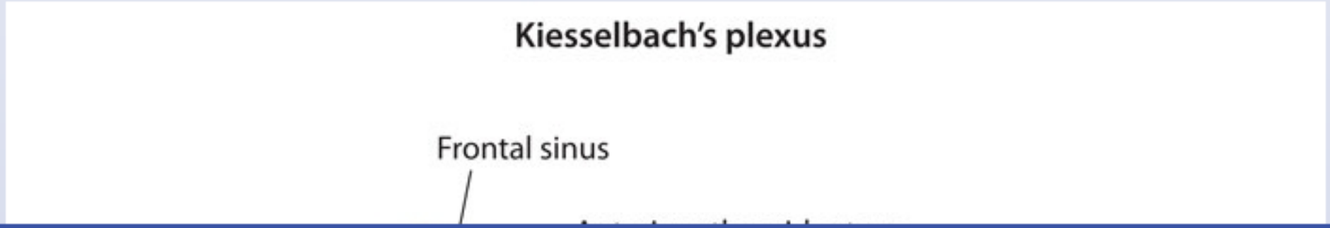

## Kiesselbach's plexus

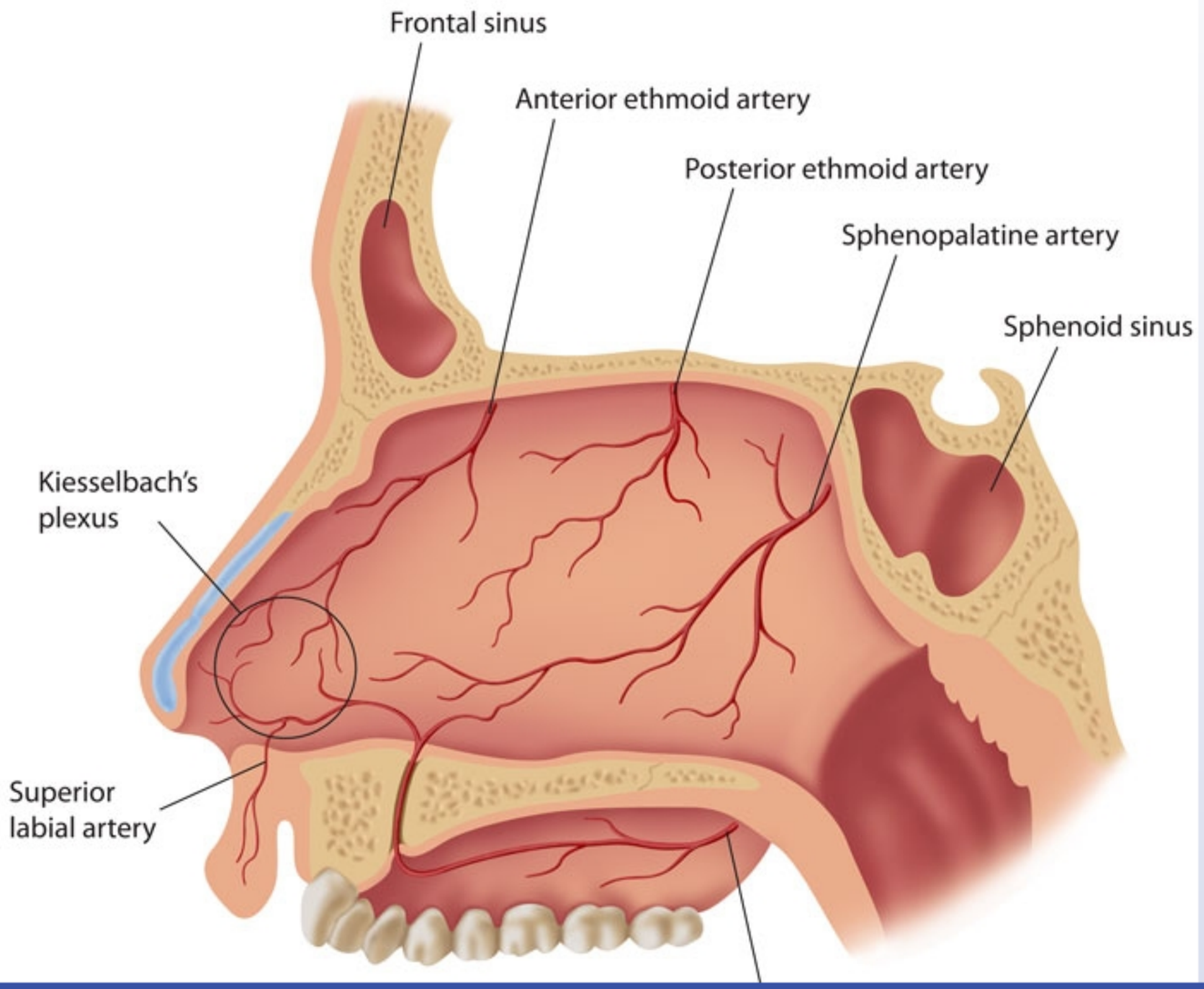

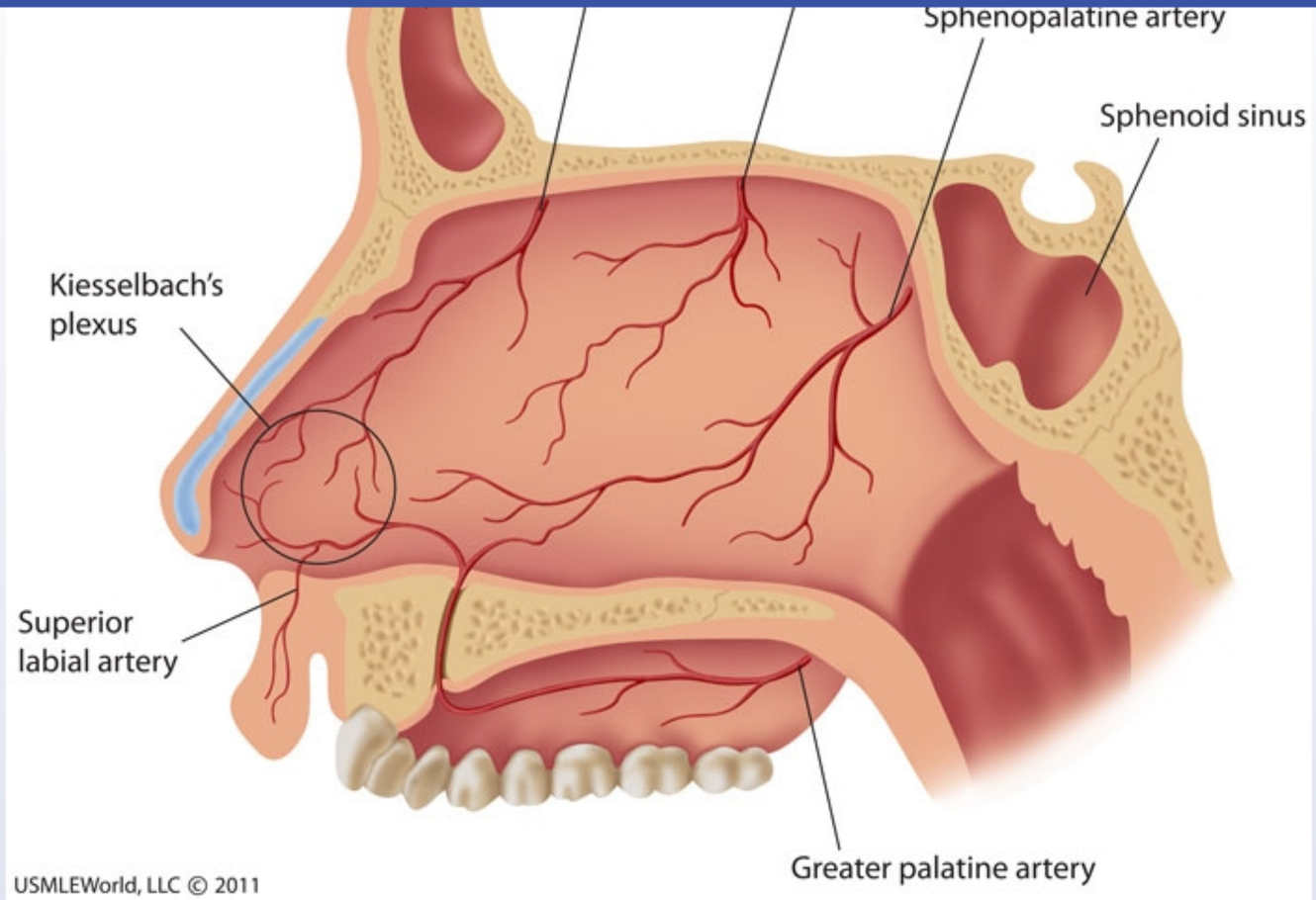


The nasal mucosa is highly vascular and easily irritated by trauma (eg, nose-picking), mucosal dryness, foreign body insertion, and rhinitis (eg, allergy, infection). **Epistaxis** is very common in children and may be classified as anterior or posterior, depending on the bleeding source. Anterior nosebleeds are by far the most common, and the vast majority occur within the vascular watershed area of the **nasal septum** (anteroinferior part of the nasal septal mucosa) known as **Kiesselbach plexus**. Anastomosis of the following vessels occurs in this region:

- Septal branch of the **anterior ethmoidal artery**
- Lateral nasal branch of the **sphenopalatine artery**

The nasal mucosa is highly vascular and easily irritated by trauma (eg, nose-picking), mucosal dryness, foreign body insertion, and rhinitis (eg, allergy, infection). **Epistaxis** is very common in children and may be classified as anterior or posterior, depending on the bleeding source. Anterior nosebleeds are by far the most common, and the vast majority occur within the vascular watershed area of the **nasal septum** (anteroinferior part of the nasal septal mucosa) known as **Kiesselbach plexus**. Anastomosis of the following vessels occurs in this region:

- Septal branch of the **anterior ethmoidal artery**
- Lateral nasal branch of the **sphenopalatine artery**
- Septal branch of the **superior labial artery** (branch of the facial artery)

Management is directed at stopping the bleeding from Kiesselbach plexus, preferably by direct compression of the nasal alae. Cautery (eg, silver nitrate) of the area surrounding the bleeding site may be necessary for persistent bleeding.

**(Choices A and B)** The lateral nasal wall contains the superior, middle, and inferior turbinates (also known as conchae). These 3 bony projections are covered with mucous membrane; they warm, humidify, and filter inspired air and expand and contract in response to environmental changes (eg, temperature, humidity, allergens). The turbinates form corresponding meatuses that serve as drainage pathways. The superior meatus provides drainage for the sphenoidal and posterior ethmoidal sinuses. The middle meatus drains the frontal, maxillary, and anterior ethmoidal sinuses and is the most common site of nasal polyps. The inferior meatus drains the nasolacrimal duct.

**(Choices D and E)** Branches of the sphenopalatine artery supply the posterolateral wall and posterior choanae. These posterolateral branches are the most likely source of posterior nosebleeds. Posterior epistaxis is usually severe and cannot be treated with cautery.

**Educational objective:**
Epistaxis is commonly caused by irritation of the highly vascular mucosa at the anterior nasal septum. The anterior nasal septum contains the Kiesselbach plexus. The anterior ethmoidal, sphenopalatine, and superior labial arteries anastomose in this region.

**References**

- Fifteen-minute consultation: investigation and management of childhood epistaxis.
- Interventions for recurrent idiopathic epistaxis (nosebleeds) in children.

Anatomy Ear, Nose & Throat (ENT) Epistaxis

The nasal mucosa is highly vascular and easily irritated by trauma (eg, nose-picking), mucosal dryness, foreign body insertion, and rhinitis (eg

Exhibit Display

## How to stop epistaxis

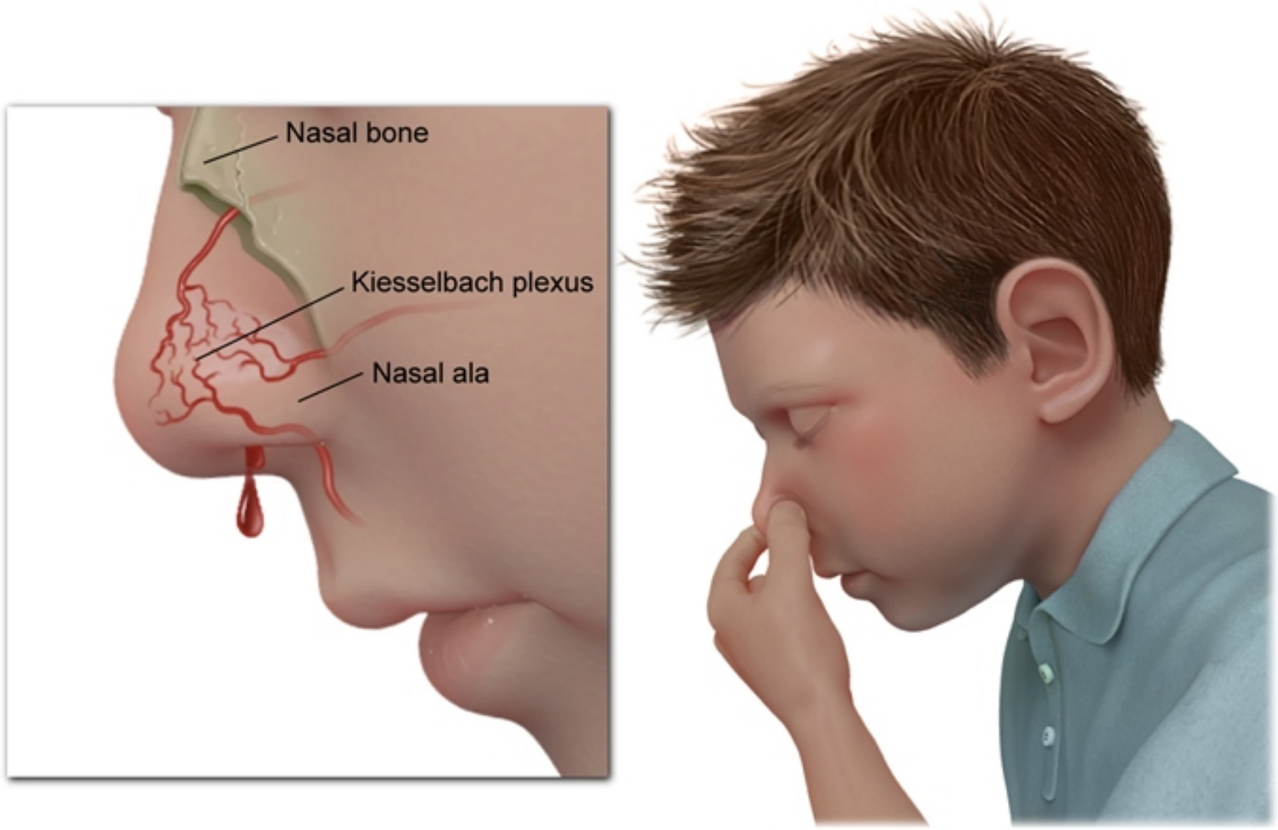


Nasal alae are compressed to stop blood flow.

©UWorld

Zoom In | Zoom Out | Reset | Add To New Card | Existing Card

Anatomy | Ear, Nose & Throat (ENT) | Epistaxis

The nasal mucosa is highly vascular and easily irritated by trauma (eg, nose-picking), mucosal dryness, foreign body insertion, and rhinitis (eg

**Exhibit Display**

**Anatomy of the nasal cavity & nasopharynx**

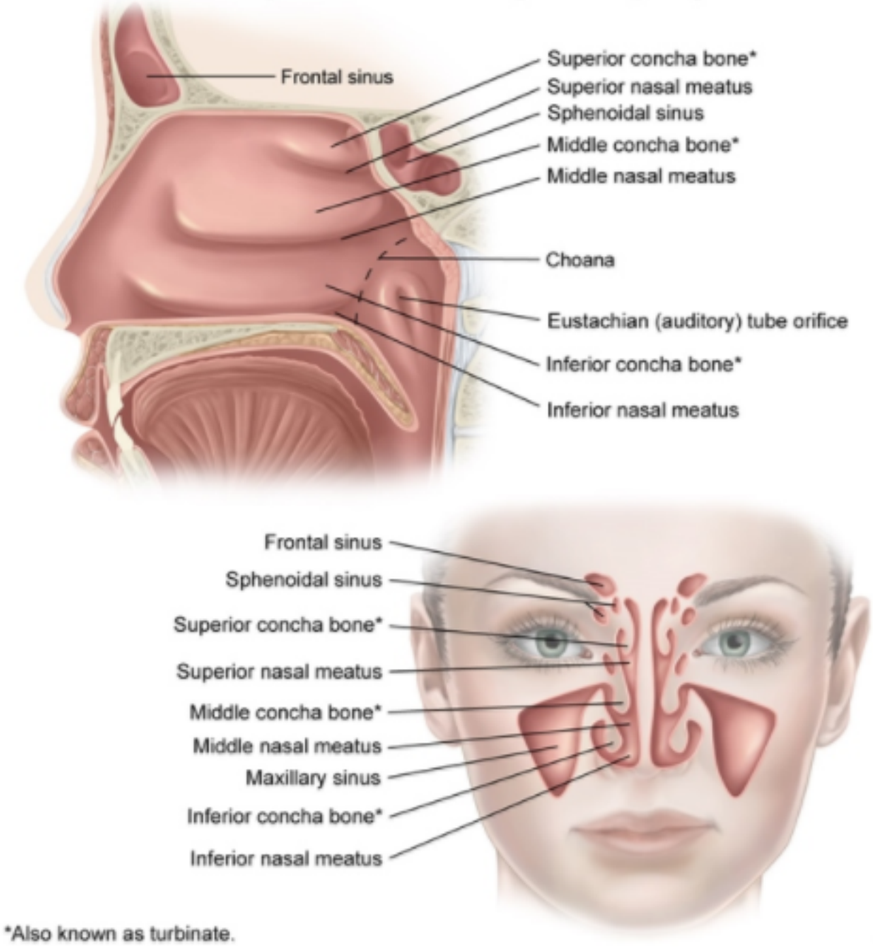


*Also known as turbinate.

©UWorld

Zoom In | Zoom Out | Reset | Add To New Card | Existing Card

Anatomy | Ear, Nose & Throat (ENT) | Epistaxis

A 23-year-old man comes to the emergency department due to a sensation of food being stuck in his throat. His symptoms started 2 hours ago after eating fish at a local seafood restaurant. He has tried swallowing multiple times to clear the food with no relief. The patient has no difficulty with breathing. He does not appear to be in significant distress on physical examination. Laryngoscopy reveals a fish bone lodged in the left piriform recess. During retrieval of the fish bone, a nerve is injured deep to the mucosa overlying the recess. Which of the following is most likely to be impaired in this patient?

A. Cough reflex
B. Gag reflex
C. Mastication
D. Salivation
E. Taste sensation

Submit

A 23-year-old man comes to the emergency department due to a sensation of food being stuck in his throat. His symptoms started 2 hours ago after eating fish at a local seafood restaurant. He has tried swallowing multiple times to clear the food with no relief. The patient has no difficulty with breathing. He does not appear to be in significant distress on physical examination. Laryngoscopy reveals a fish bone lodged in the left piriform recess. During retrieval of the fish bone, a nerve is injured deep to the mucosa overlying the recess. Which of the following is most likely to be impaired in this patient?

- ✓ A. Cough reflex (39%)
- B. Gag reflex (53%)
- C. Mastication (1%)
- D. Salivation (2%)
- E. Taste sensation (4%)

Omitted
Correct answer
A

39%
Answered correctly

03 secs
Time Spent

06/01/2020
Last Updated

Explanation

Posterior view of pharynx

## Posterior view of pharynx

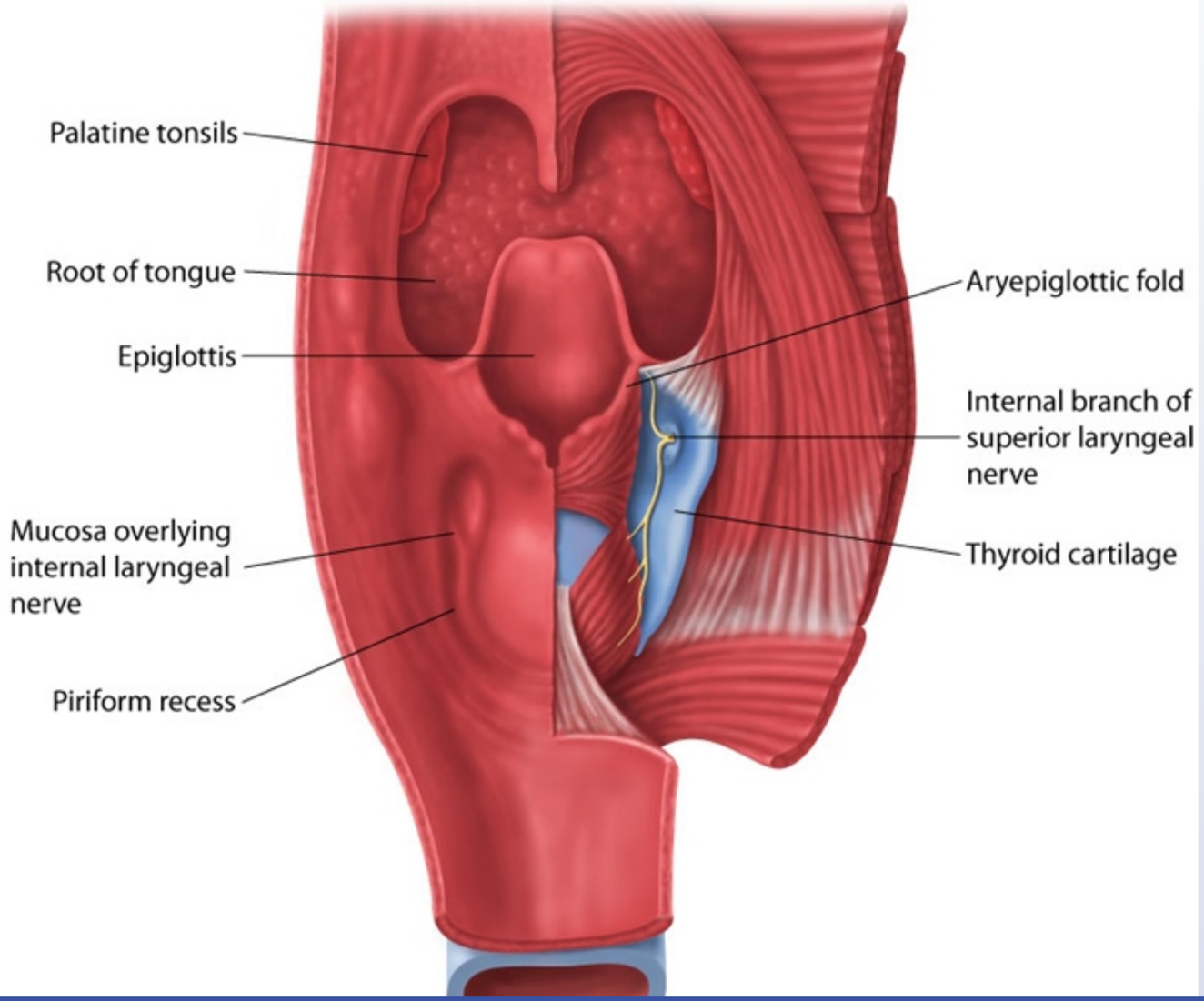

The **piriform recesses** are small cavities that lie on either side of the laryngeal orifice. They are bounded medially by the aryepiglottic folds and laterally by the thyroid cartilage and thyrohyoid membrane. During normal swallowing, food is diverted by the epiglottis laterally through the piriform recesses into the esophagus without endangering the airway.

A thin layer of mucosa overlying the piriform recess is all that protects the superficially coursing **internal laryngeal nerve**, a branch of the superior laryngeal nerve (part of the vagus nerve [CN X]). Unlike the recurrent and external laryngeal nerves that carry motor fibers to the muscles involved in vocal cord function, the internal laryngeal nerve contains only sensory and autonomic fibers. It mediates the afferent limb of the cough reflex by **carrying sensation** from the mucosa **superior to the vocal cords**.

**Damage** to the internal laryngeal nerve can occur when foreign bodies (eg, chicken or fish bones) become lodged in the piriform recess or during attempts to retrieve them. The resulting reduction in laryngeal sensation can **impair the cough reflex**.

**(Choice B)** The afferent limb of the gag reflex is mediated predominantly by the glossopharyngeal nerve (CN IX), whereas the efferent limb is carried by the vagus nerve (CN X). Although the internal laryngeal nerve is a branch of CN X, it does not carry motor fibers and is not involved in the gag reflex.

**(Choice C)** The muscles of mastication are innervated by the mandibular branch of the trigeminal nerve (CN $V_3$). This nerve is involved in the jaw jerk reflex, which is typically prominent only in patients with upper motor neuron lesions.

**(Choice D)** Salivation is mediated by the glossopharyngeal nerve (which innervates the parotid gland via the otic ganglion) and the facial nerve (which innervates submandibular and sublingual glands via the submandibular ganglion). These nerves do not lie in close proximity to the piriform recess.

**(Choice E)** Although the internal laryngeal nerve carries taste sensation from the root of the tongue and epiglottis, its role in the perception of taste is extremely minor. Taste sensation is primarily mediated by glossopharyngeal nerve (posterior one-third of the tongue and oropharynx) and facial nerve (anterior two-thirds of the tongue).

**Educational objective:**
The internal laryngeal nerve mediates the afferent limb of the cough reflex above the vocal cords. Foreign bodies (eg, fish bones) can become lodged in the piriform recess and may cause damage to the nerve, impairing the cough reflex.

A thin layer of mucosa overlying the piriform recess is all that protects the superficially coursing **internal laryngeal nerve**, a branch of the superior laryngeal nerve (part of the vagus nerve [CN X]). Unlike the recurrent and external laryngeal nerves that carry motor fibers to the muscles involved in vocal cord function, the internal laryngeal nerve contains only sensory and autonomic fibers. It mediates the afferent limb of the cough reflex by **carrying sensation** from the mucosa **superior to the vocal cords**.

**Damage** to the internal laryngeal nerve can occur when foreign bodies (eg, chicken or fish bones) become lodged in the piriform recess or during attempts to retrieve them. The resulting reduction in laryngeal sensation can **impair the cough reflex**.

**(Choice B)** The afferent limb of the gag reflex is mediated predominantly by the glossopharyngeal nerve (CN IX), whereas the efferent limb is carried by the vagus nerve (CN X). Although the internal laryngeal nerve is a branch of CN X, it does not carry motor fibers and is not involved in the gag reflex.

**(Choice C)** The muscles of mastication are innervated by the mandibular branch of the trigeminal nerve (CN $V_3$). This nerve is involved in the jaw jerk reflex, which is typically prominent only in patients with upper motor neuron lesions.

**(Choice D)** Salivation is mediated by the glossopharyngeal nerve (which innervates the parotid gland via the otic ganglion) and the facial nerve (which innervates submandibular and sublingual glands via the submandibular ganglion). These nerves do not lie in close proximity to the piriform recess.

**(Choice E)** Although the internal laryngeal nerve carries taste sensation from the root of the tongue and epiglottis, its role in the perception of taste is extremely minor. Taste sensation is primarily mediated by glossopharyngeal nerve (posterior one-third of the tongue and oropharynx) and facial nerve (anterior two-thirds of the tongue).

**Educational objective:**
The internal laryngeal nerve mediates the afferent limb of the cough reflex above the vocal cords. Foreign bodies (eg, fish bones) can become lodged in the piriform recess and may cause damage to the nerve, impairing the cough reflex.

| Anatomy | Ear, Nose & Throat (ENT) | Foreign body aspiration |
|---|---|---|
| Subject | System | Topic |

Copyright © UWorld. All rights reserved.

The **piriform recesses** are small cavities that lie on either side of the laryngeal orifice. They are bounded medially by the aryepiglottic folds and

Exhibit Display

**Innervation of cricothyroid muscle**

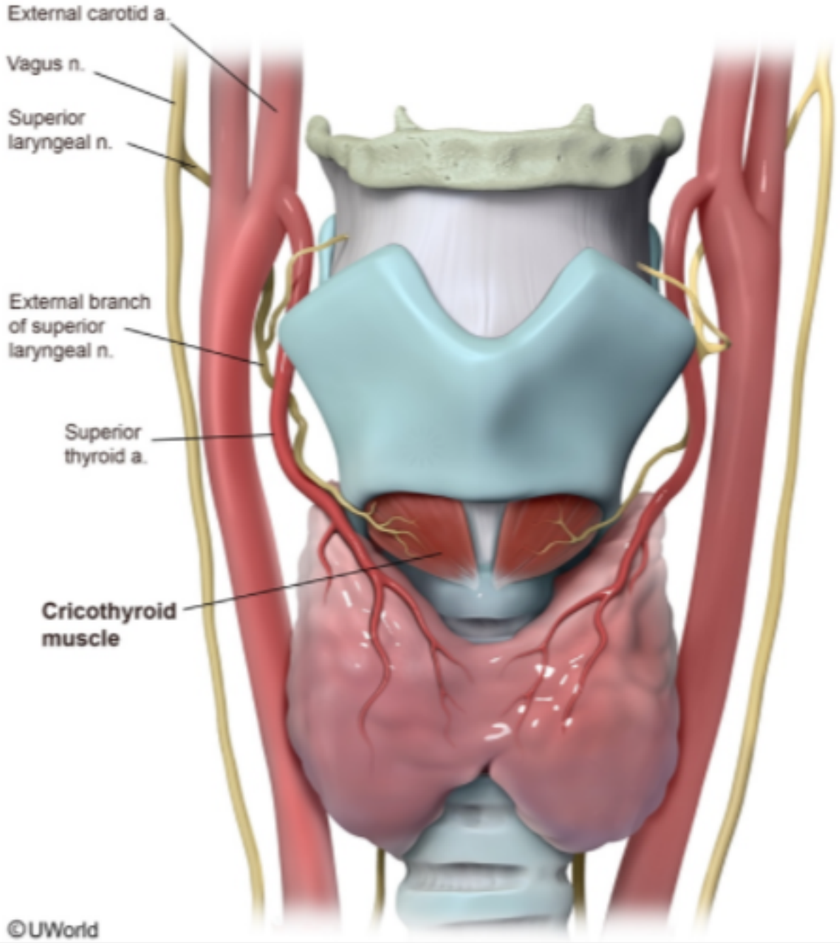


Zoom In | Zoom Out | Reset | Add To New Card | Existing Card

Anatomy | Ear, Nose & Throat (ENT) | Foreign body aspiration

The **piriform recesses** are small cavities that lie on either side of the laryngeal orifice. They are bounded medially by the aryepiglottic folds and

**Exhibit Display**

**Cranial nerve reflexes**

| Reflex | Effect | Afferent | Efferent |
|---|---|---|---|
| Pupillary light reflex | Light-induced pupil constriction | II | III |
| Corneal reflex | Corneal stimulation causes orbicularis oculi to contract eyelids | V1 (ophthalmic branch) | VII |
| Jaw-jerk reflex | Stretch reflex stimulating masseter contraction | V3 (sensory from muscle spindles) | V3 |
| Vestibulo-ocular reflex | Compensatory eye movements that provide image stabilization when head/body moves | VIII (vestibular component) | III, IV, VI |
| Carotid sinus reflex | Increased carotid sinus pressure causes decreased heart rate & blood pressure | IX | X (sympathetic tone also inhibited) |
| Cough reflex | Cough induced by upper respiratory tract irritation | X | X |
| Gag reflex | Reflex contraction of the pharyngeal constrictor muscles evoked by touching the back of the throat | IX | X |

©UWorld

Zoom In Zoom Out Reset Add To New Card | Existing Card

Anatomy Ear, Nose & Throat (ENT) Foreign body aspiration

A 30-year-old woman comes to the emergency department after a seizure. The patient reports pain on the left side of her face and is unable to fully open or close her mouth. She is drooling. On examination, the jaw deviates to the right and the left mandibular condyle is very prominent with a palpable depression posterior to it. The patient is diagnosed with an anterior dislocation of the left temporomandibular joint. The jaw is most likely maintained in a dislocated position due to continued spasm of which of the following muscles?

- A. Buccinator
- B. Genioglossus
- C. Lateral pterygoid
- D. Sternocleidomastoid
- E. Superior pharyngeal constrictor
- F. Zygomaticus major

Submit

A 30-year-old woman comes to the emergency department after a seizure. The patient reports pain on the left side of her face and is unable to fully open or close her mouth. She is drooling. On examination, the jaw deviates to the right and the left mandibular condyle is very prominent with a palpable depression posterior to it. The patient is diagnosed with an anterior dislocation of the left temporomandibular joint. The jaw is most likely maintained in a dislocated position due to continued spasm of which of the following muscles?

- A. Buccinator (6%)
- B. Genioglossus (0%)
- ✓ C. Lateral pterygoid (85%)
- D. Sternocleidomastoid (1%)
- E. Superior pharyngeal constrictor (0%)
- F. Zygomaticus major (4%)

Omitted
Correct answer
C

85%
Answered correctly

02 secs
Time Spent

05/15/2020
Last Updated

Explanation

**Lateral pterygoid function**

Lateral pterygoid

# Lateral pterygoid function

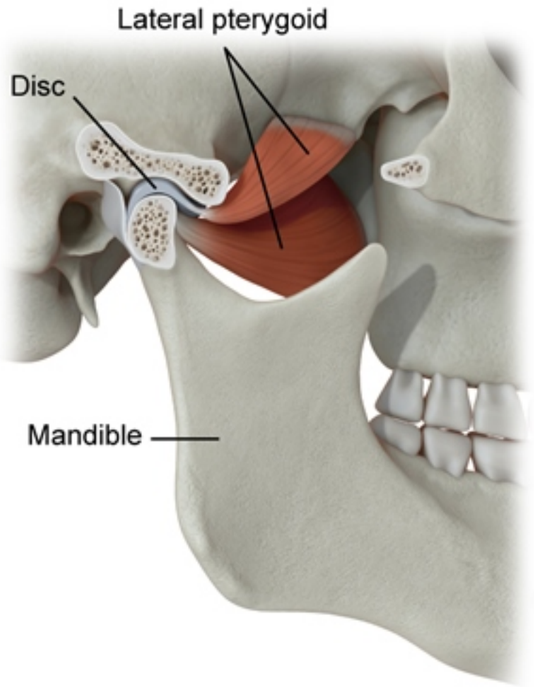


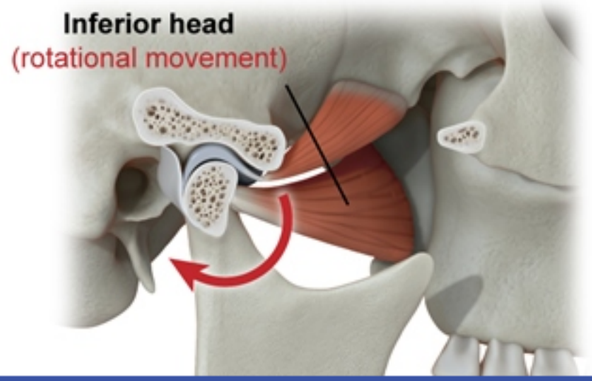


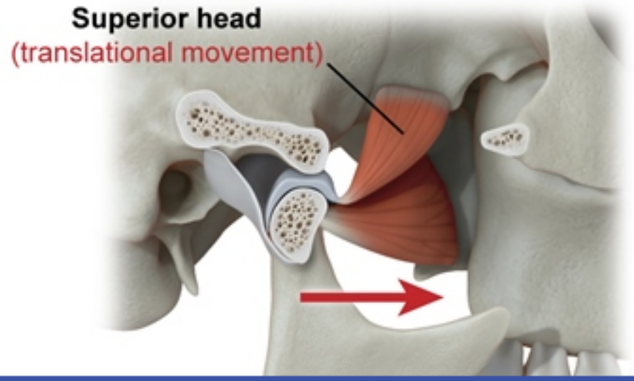

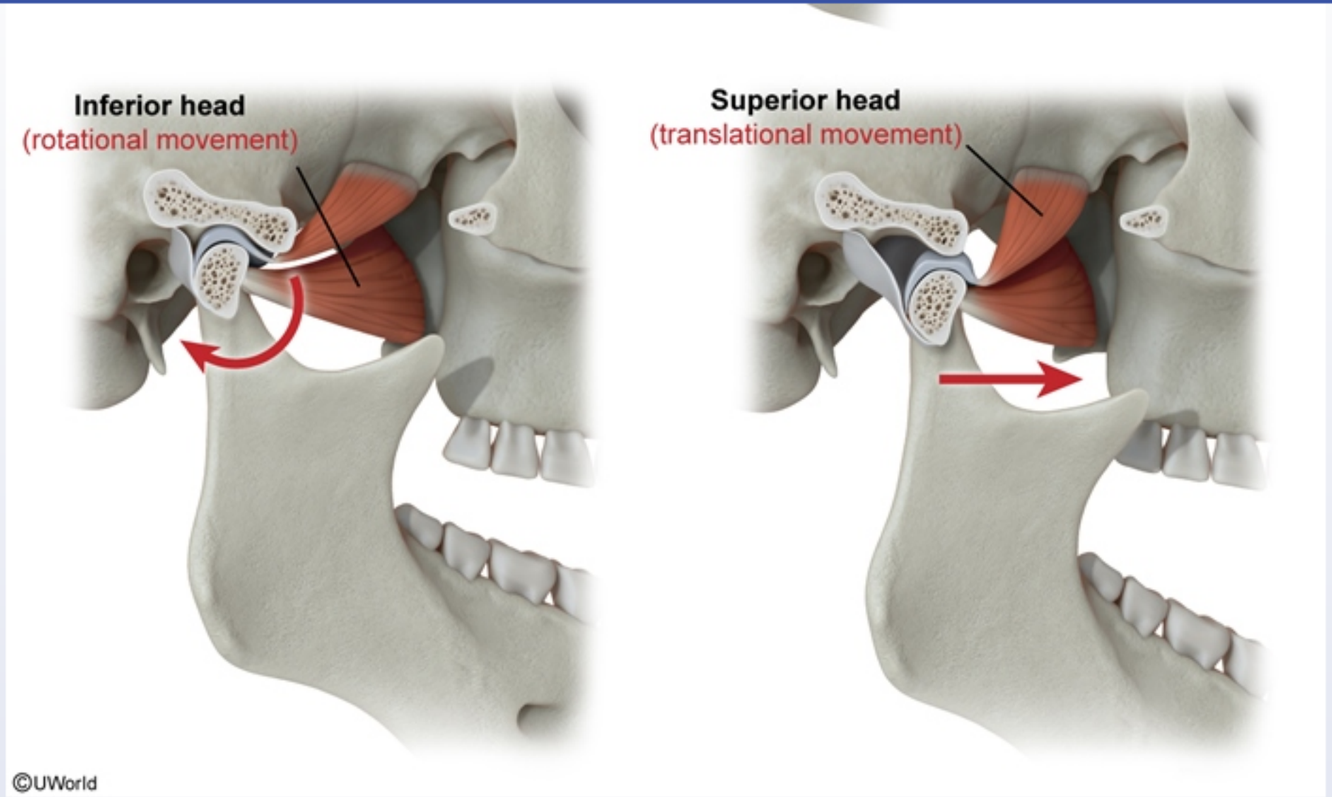


This patient has an anterior dislocation of the **temporomandibular joint** (TMJ), the synovial joint that opens and closes the jaw. The joint is formed by the mandibular condyle that sits in the glenoid fossa of the squamous portion of the temporal bone.

TMJ opening involves a complex movement that has both hinge and sliding components:

- The initial movement is rotational (ie, hinge) and driven by the **lateral pterygoid muscles**, which are the only muscles of mastication that aid in **depressing the mandible** (ie, opening the jaw).
- As the jaw opens, the ligaments become taut, stopping further rotation.
- Further action by the lateral pterygoids results in translational movement (ie, condyle slides anteriorly) that opens the jaw fully.

©UWorld

This patient has an anterior dislocation of the **temporomandibular joint** (TMJ), the synovial joint that opens and closes the jaw. The joint is formed by the mandibular condyle that sits in the glenoid fossa of the squamous portion of the temporal bone.

TMJ opening involves a complex movement that has both hinge and sliding components:

- The initial movement is rotational (ie, hinge) and driven by the **lateral pterygoid muscles**, which are the only muscles of mastication that aid in **depressing the mandible** (ie, opening the jaw).
- As the jaw opens, the ligaments become taut, stopping further rotation.
- Further action by the lateral pterygoids results in translational movement (ie, condyle slides anteriorly) that opens the jaw fully.

TMJ dislocation occurs when translational movement is exaggerated due to **extreme jaw opening** (eg, yawning, orotracheal intubation, **seizure**) that causes displacement of the condyle anteriorly out of the glenoid fossa. Stretching of the ligaments causes significant pain and spasm of the muscles of mastication. This **muscle spasm** (specifically of the lateral pterygoids that aid jaw opening) **prevents spontaneous resolution** of the dislocation; manual reduction is usually necessary.

**(Choice A)** The buccinator muscle underlies the cheek. It holds the cheek close to the teeth to control food boluses during chewing but is not involved in movement of the jaw.

**(Choice B)** The genioglossus muscles form the body of the tongue. Although they originate on the tubercle of the mandible (and insert into the hyoid bone and the bottom of the tongue), they are responsible for tongue protrusion rather than mandibular movement.

**(Choice D)** The sternocleidomastoid muscles originate at the sternum and the clavicle and insert on the mastoid tip. They rotate the head (when acting independently) or flex the neck (when acting in concert).

**(Choice E)** The superior pharyngeal constrictor forms portions of the posterior and lateral oropharyngeal walls. Muscle contraction propels food and liquid inferiorly into the esophagus during swallowing.

**(Choice F)** The zygomaticus major originates from the zygomatic bone and inserts onto the angle of the mouth. Contraction pulls the angle of the mouth laterally and superiorly during a smile.

**Educational objective:**

that causes displacement of the condyle anteriorly out of the glenoid fossa. Stretching of the ligaments causes significant pain and spasm of the muscles of mastication. This **muscle spasm** (specifically of the lateral pterygoids that aid jaw opening) **prevents spontaneous resolution** of the dislocation; manual reduction is usually necessary.

**(Choice A)** The buccinator muscle underlies the cheek. It holds the cheek close to the teeth to control food boluses during chewing but is not involved in movement of the jaw.

**(Choice B)** The genioglossus muscles form the body of the tongue. Although they originate on the tubercle of the mandible (and insert into the hyoid bone and the bottom of the tongue), they are responsible for tongue protrusion rather than mandibular movement.

**(Choice D)** The sternocleidomastoid muscles originate at the sternum and the clavicle and insert on the mastoid tip. They rotate the head (when acting independently) or flex the neck (when acting in concert).

**(Choice E)** The superior pharyngeal constrictor forms portions of the posterior and lateral oropharyngeal walls. Muscle contraction propels food and liquid inferiorly into the esophagus during swallowing.

**(Choice F)** The zygomaticus major originates from the zygomatic bone and inserts onto the angle of the mouth. Contraction pulls the angle of the mouth laterally and superiorly during a smile.

**Educational objective:**
The lateral pterygoid muscles are the only muscles of mastication that aid in depressing the mandible (ie, opening the jaw). Spasm of the lateral pterygoids prevents spontaneous reduction of an anterior dislocation of the temporomandibular joint.

**References**

- Temporomandibular joint dislocation.
- The emerging role of botulinum toxin in the treatment of temporomandibular disorders

| Anatomy | Ear, Nose & Throat (ENT) | Temporomandibular disorders |
|---|---|---|
| Subject | System | Topic |

Copyright © UWorld. All rights reserved.

that causes displacement of the condyle anteriorly out of the glenoid fossa. Stretching of the ligaments causes significant pain and spasm of the

**Exhibit Display**

**Muscles of facial expression**

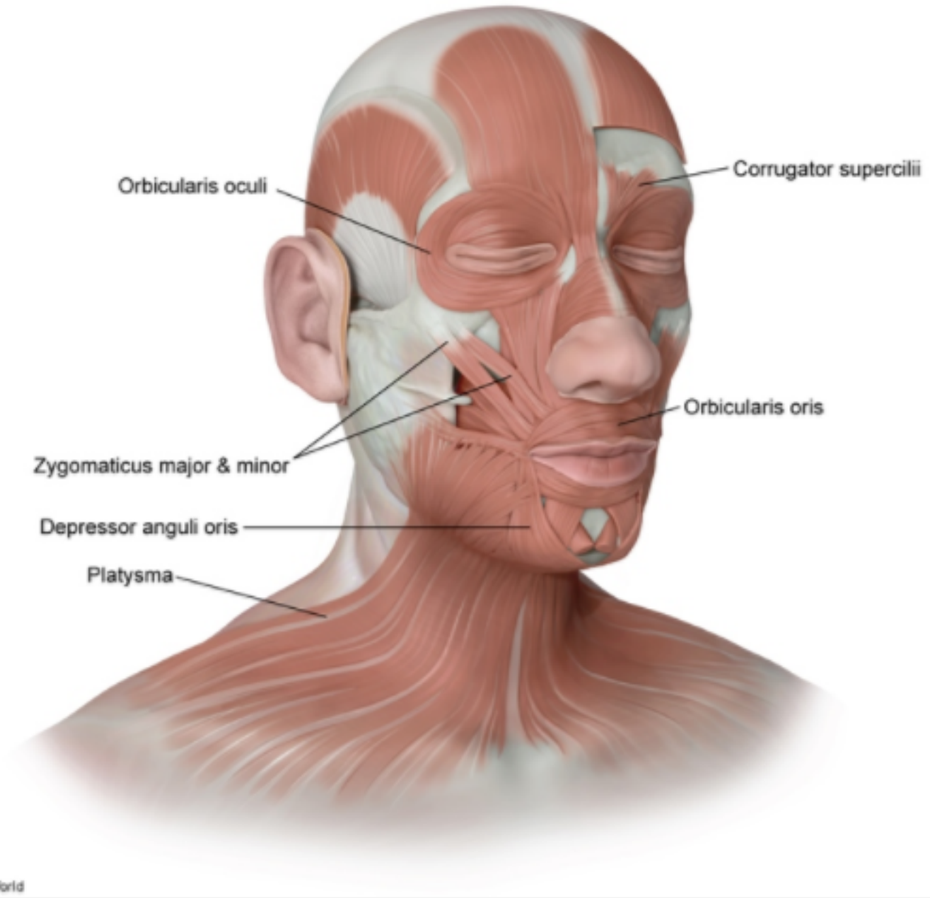


Zoom In Zoom Out Reset Add To Flash Card

A 33-year-old man comes to the office due to trouble swallowing and a chronic sore throat. He has no chronic medical conditions and does not use tobacco or alcohol. Physical examination shows an enlarged, ulcerated right tonsil. Biopsy of the ulcerated lesion reveals infiltrating nests of moderately differentiated squamous cells. Immunohistochemistry is positive for p16, suggesting that the tumor is likely due to human papilloma virus. Further imaging studies for cancer staging are planned. This patient's tumor is most likely to spread first to which of the following locations?

- A. Adenoid tissue
- B. Adrenal glands
- C. Gray-white matter junction
- D. Jugular lymph nodes
- E. Lung parenchyma
- F. Vertebral bodies

Submit

A 33-year-old man comes to the office due to trouble swallowing and a chronic sore throat. He has no chronic medical conditions and does not use tobacco or alcohol. Physical examination shows an enlarged, ulcerated right tonsil. Biopsy of the ulcerated lesion reveals infiltrating nests of moderately differentiated squamous cells. Immunohistochemistry is positive for p16, suggesting that the tumor is likely due to human papilloma virus. Further imaging studies for cancer staging are planned. This patient's tumor is most likely to spread first to which of the following locations?

- A. Adenoid tissue (35%)
- B. Adrenal glands (1%)
- C. Gray-white matter junction (1%)
- ✓ D. Jugular lymph nodes (56%)
- E. Lung parenchyma (4%)
- F. Vertebral bodies (1%)

Omitted
Correct answer
D

56%
Answered correctly

02 secs
Time Spent

02/24/2020
Last Updated

Explanation

Most **carcinomas**, including head and neck squamous cell carcinoma, **spread first** from the primary site of the tumor to **regional lymph nodes** via the **lymphatics**. In this patient with a tonsillar squamous cell carcinoma, this spread would be to the upper anterior cervical (ie, jugular) lymph nodes. Assessment of regional lymph node status is important for tumor staging based on the **TNM staging system**, which evaluates the size and characteristics of the **T**umor, regional lymph **N**ode involvement, and distant **M**etastases.

**(Choice A)** Similar to the tonsils, adenoid tissue is also lymphatic tissue in the head and neck that can harbor a primary site of head and neck

Most **carcinomas**, including head and neck squamous cell carcinoma, **spread first** from the primary site of the tumor to **regional lymph nodes** via the **lymphatics**. In this patient with a tonsillar squamous cell carcinoma, this spread would be to the upper anterior cervical (ie, jugular) lymph nodes. Assessment of regional lymph node status is important for tumor staging based on the **TNM staging system**, which evaluates the size and characteristics of the **T**umor, regional lymph **N**ode involvement, and distant **M**etastases.

**(Choice A)** Similar to the tonsils, adenoid tissue is also lymphatic tissue in the head and neck that can harbor a primary site of head and neck squamous cell carcinoma. However, it is located in the nasopharynx rather than the oropharynx. The spread of cancer is typically to regional lymph nodes rather than to other mucosal sites in the head and neck.

**(Choices B, C, and F)** Although these are possible sites of distant cancer metastases, they are less commonly associated with metastatic head and neck cancer. Common primary sources for metastases to these sites include:

- Adrenal gland metastases: breast cancer, renal cell carcinoma, and melanoma
- Brain metastases (gray-white matter junction): lung cancer
- Vertebral body metastases: prostate cancer

However, the first site of spread of most carcinomas (including head and neck cancer) is the regional lymph nodes.

**(Choice E)** The lung parenchyma is the most common site for distant metastases from head and neck cancer. However, regional lymph node spread is typically seen first.

**Educational objective:**
Head and neck squamous cell carcinomas typically spread first to the anterior cervical (ie, jugular) lymph nodes via the lymphatics. Distant spread occurs after regional lymph node involvement.

**References**

- Incidence and sites of distant metastases from head and neck cancer.

| Anatomy | Hematology & Oncology | Lymphatic drainage |
|---|---|---|
| Subject | System | Topic |

Copyright © UWorld. All rights reserved.

A 26-year-old woman comes to the office due to pain in her right jaw that is deep, achy, and worse in the morning. It radiates to her temple and is associated with headaches. The patient also has neck pain and stiffness, especially on the right side. When she chews, she hears a clicking noise in her right ear. The patient is in a competitive graduate study program and has been under significant stress. Her roommate says that she has been grinding her teeth at night. Physical examination will likely reveal spasms of which of the following muscles?

A. Buccinator

B. Levator veli palatini

C. Masseter

D. Mylohyoid

E. Omohyoid

Submit

A 26-year-old woman comes to the office due to pain in her right jaw that is deep, achy, and worse in the morning. It radiates to her temple and is associated with headaches. The patient also has neck pain and stiffness, especially on the right side. When she chews, she hears a clicking noise in her right ear. The patient is in a competitive graduate study program and has been under significant stress. Her roommate says that she has been grinding her teeth at night. Physical examination will likely reveal spasms of which of the following muscles?

A. Buccinator (6%)

B. Levator veli palatini (2%)

✓ C. Masseter (89%)

D. Mylohyoid (1%)

E. Omohyoid (0%)

Omitted
Correct answer
C

89%
Answered correctly

02 secs
Time Spent

05/11/2020
Last Updated

## Explanation

This patient has jaw pain, a clicking noise when she chews, and associated headaches and neck stiffness, which is suggestive of **temporomandibular joint (TMJ) syndrome**. The underlying etiology of TMJ syndrome is multifactorial and includes TMJ derangement (eg, jaw misalignment, trauma), and hypersensitivity of the mandibular nerve (CN V3). **Mechanical derangement** of the TMJ can result in irritation and hypersensitivity of CN V3, leading to pathologic contraction of the **masseter** and **pterygoid** muscles (which worsens jaw pain and dysfunction). **Spasms** of these muscles can sometimes be palpated along the mandibular ramus.

Repetitive jaw motions (eg, gum chewing, teeth grinding) are thought to contribute to the development of TMJ syndrome due to increased

This patient has jaw pain, a clicking noise when she chews, and associated headaches and neck stiffness, which is suggestive of **temporomandibular joint (TMJ) syndrome**. The underlying etiology of TMJ syndrome is multifactorial and includes TMJ derangement (eg, jaw misalignment, trauma), and hypersensitivity of the mandibular nerve (CN V3). **Mechanical derangement** of the TMJ can result in irritation and hypersensitivity of CN V3, leading to pathologic contraction of the **masseter** and **pterygoid** muscles (which worsens jaw pain and dysfunction). **Spasms** of these muscles can sometimes be palpated along the mandibular ramus.

Repetitive jaw motions (eg, gum chewing, teeth grinding) are thought to contribute to the development of TMJ syndrome due to increased workload and strain on the joint. Similar to some other musculoskeletal pain disorders (eg, tension headache), TMJ pain also seems to be related to psychiatric conditions and emotional distress.

**(Choice A)** The buccinator muscle underlies the cheek and holds it close to the teeth to control the food bolus when chewing. It is innervated by a branch of the facial nerve (CN VII).

**(Choice B)** The levator veli palatini elevates the soft palate during swallowing to prevent food from refluxing into the nasopharynx. It is innervated by the pharyngeal branch of the vagus nerve (CN X).

**(Choice D)** The mylohyoid runs from the mandible to the hyoid bone, forming the floor of mouth. Although it is innervated by a branch of CN V3, it does not help close the jaw. It acts during swallowing to elevate the tongue and hyoid bone, which propels the food bolus into the posterior oral cavity and oropharynx.

**(Choice E)** The omohyoid muscle travels from the hyoid bone to the clavicle and helps depress the hyoid during speech or swallowing. It is innervated by the ansa cervicalis, a branch of the cervical plexus.

**Educational objective:**
Temporomandibular joint disorder is associated with dysfunction of the temporomandibular joint and hypersensitivity of the mandibular nerve (CN V3). This can result in pathologic contraction of the muscles of mastication, including the masseter and pterygoids.

**References**

- Temporomandibular disorders.
- Depression, pain, exposure to stressful life events, and long-term outcomes in temporomandibular disorder patients.

A 65-year-old man comes to the office with a 4-month history of persistent left ear pain that is slowly worsening. He is also having some difficulty swallowing. The patient has no chronic medical conditions but has smoked 1 pack of cigarettes per day for the last 46 years. On examination, the external auditory canal is patent and the tympanic membrane is clear with no middle ear effusion. There is an enlarged lymph node in the left anterior neck. Flexible fiberoptic laryngoscopy reveals an ulcerative mass on the posterior pharyngeal wall of the hypopharynx. Involvement of which of the following nerves is most likely responsible for this patient's ear pain?

- A. Trigeminal nerve
- B. Facial nerve
- C. Vestibulocochlear nerve
- D. Vagus nerve
- E. Hypoglossal nerve
- F. Great auricular nerve

Submit

A 65-year-old man comes to the office with a 4-month history of persistent left ear pain that is slowly worsening. He is also having some difficulty swallowing. The patient has no chronic medical conditions but has smoked 1 pack of cigarettes per day for the last 46 years. On examination, the external auditory canal is patent and the tympanic membrane is clear with no middle ear effusion. There is an enlarged lymph node in the left anterior neck. Flexible fiberoptic laryngoscopy reveals an ulcerative mass on the posterior pharyngeal wall of the hypopharynx. Involvement of which of the following nerves is most likely responsible for this patient's ear pain?

- A. Trigeminal nerve (11%)
- B. Facial nerve (13%)
- C. Vestibulocochlear nerve (2%)
- ✓ D. Vagus nerve (57%)
- E. Hypoglossal nerve (5%)
- F. Great auricular nerve (9%)

Omitted
Correct answer
D

57%
Answered correctly

02 secs
Time Spent

04/30/2020
Last Updated

Explanation

**Referred otalgia**

## Referred otalgia

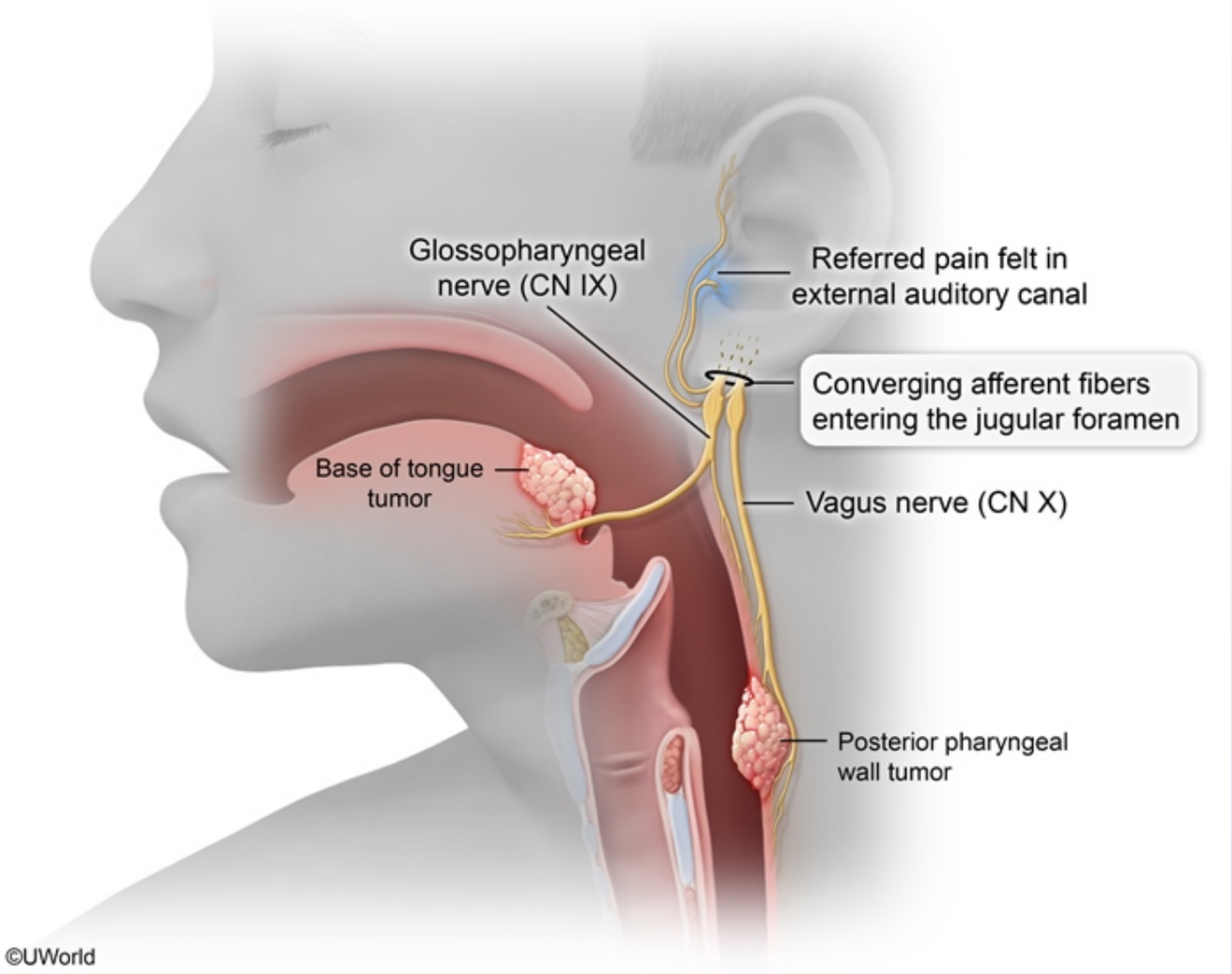


This patient has **otalgia** in the setting of a normal ear examination, which is likely **referred pain** (pain perceived at a different site than its true origin). Further evaluation shows an ulcerative mass in the hypopharynx with an enlarged lymph node, which is consistent with **mucosal head**

This patient has **otalgia** in the setting of a normal ear examination, which is likely **referred pain** (pain perceived at a different site than its true origin). Further evaluation shows an ulcerative mass in the hypopharynx with an enlarged lymph node, which is consistent with **mucosal head and neck squamous cell carcinoma** (HNSCC).

Many sources of pain in the head and neck can be referred to the ear because several cranial nerves also innervate parts of the ear. Common causes of referred ear pain include temporomandibular joint disease, dental disease, or cancer affecting the tongue base, hypopharynx, or larynx.

This patient's referred otalgia is most likely due to his hypopharyngeal carcinoma causing irritation of the **vagus nerve** (CN X). The vagus nerve has afferent fibers innervating the larynx and **hypopharynx** and also has a branch that provides afferent sensory input from the external auditory canal. Similarly, the **glossopharyngeal nerve** (CN IX), which innervates the upper pharynx and base of tongue, also provides sensory innervation to the external auditory canal and can contribute to referred otalgia from tumors in these areas.

**(Choices A, B, and F)** The trigeminal nerve (CN V) provides sensory innervation for much of the face, including parts of the ear. The facial nerve (CN VII) and great auricular nerve (originates from C2 and C3) innervate portions of the external auditory canal. Although these nerves carry sensation from the ear, they do not provide innervation to the hypopharynx.

**(Choice C)** The vestibulocochlear nerve (CN VIII) contributes special sensory (hearing, balance) from the ear but does not contribute to general sensation. Therefore, lesions that impact the vestibulocochlear nerve tend to cause hearing loss or imbalance (eg, vertigo) rather than pain.

**(Choice E)** The hypoglossal nerve (CN XII) innervates the muscles of the tongue. It has motor function only, so dysfunction tends to produce weakness (eg, deviation of the tongue) rather than pain.

**Educational objective:**
Referred otalgia is common in head and neck pathology because many cranial nerves innervate the ear (eg, CN V, VII, IX, X). In particular, tumors in the hypopharynx, larynx, or base of tongue cause referred otalgia due to sensory contributions from the glossopharyngeal and vagus nerves.

| Anatomy | Ear, Nose & Throat (ENT) | Head and neck cancers |
|---|---|---|
| Subject | System | Topic |

Copyright © UWorld. All rights reserved.

A 25-year-old woman comes to the office due to right ear pain that has worsened over the past 2 months. The pain is dull and constant and waxes and wanes. It is worse when she chews hard foods such as steak or almonds. In addition to ear pain, her ear feels stuffy and has some ringing. The patient grinds her teeth at night and previously wore a dental guard, but it broke several months ago. Ear examination is normal. Which of the following nerves is most likely responsible for this patient's ear pain?

A. Glossopharyngeal

B. Hypoglossal

C. Trigeminal

D. Vagus

E. Vestibulocochlear

Submit

A 25-year-old woman comes to the office due to right ear pain that has worsened over the past 2 months. The pain is dull and constant and waxes and wanes. It is worse when she chews hard foods such as steak or almonds. In addition to ear pain, her ear feels stuffy and has some ringing. The patient grinds her teeth at night and previously wore a dental guard, but it broke several months ago. Ear examination is normal. Which of the following nerves is most likely responsible for this patient's ear pain?

- A. Glossopharyngeal (6%)
- B. Hypoglossal (0%)
- ✓ C. Trigeminal (75%)
- D. Vagus (4%)
- E. Vestibulocochlear (12%)

Omitted
Correct answer
C

75%
Answered correctly

02 secs
Time Spent

03/23/2020
Last Updated

Explanation

## Mandibular division of trigeminal nerve

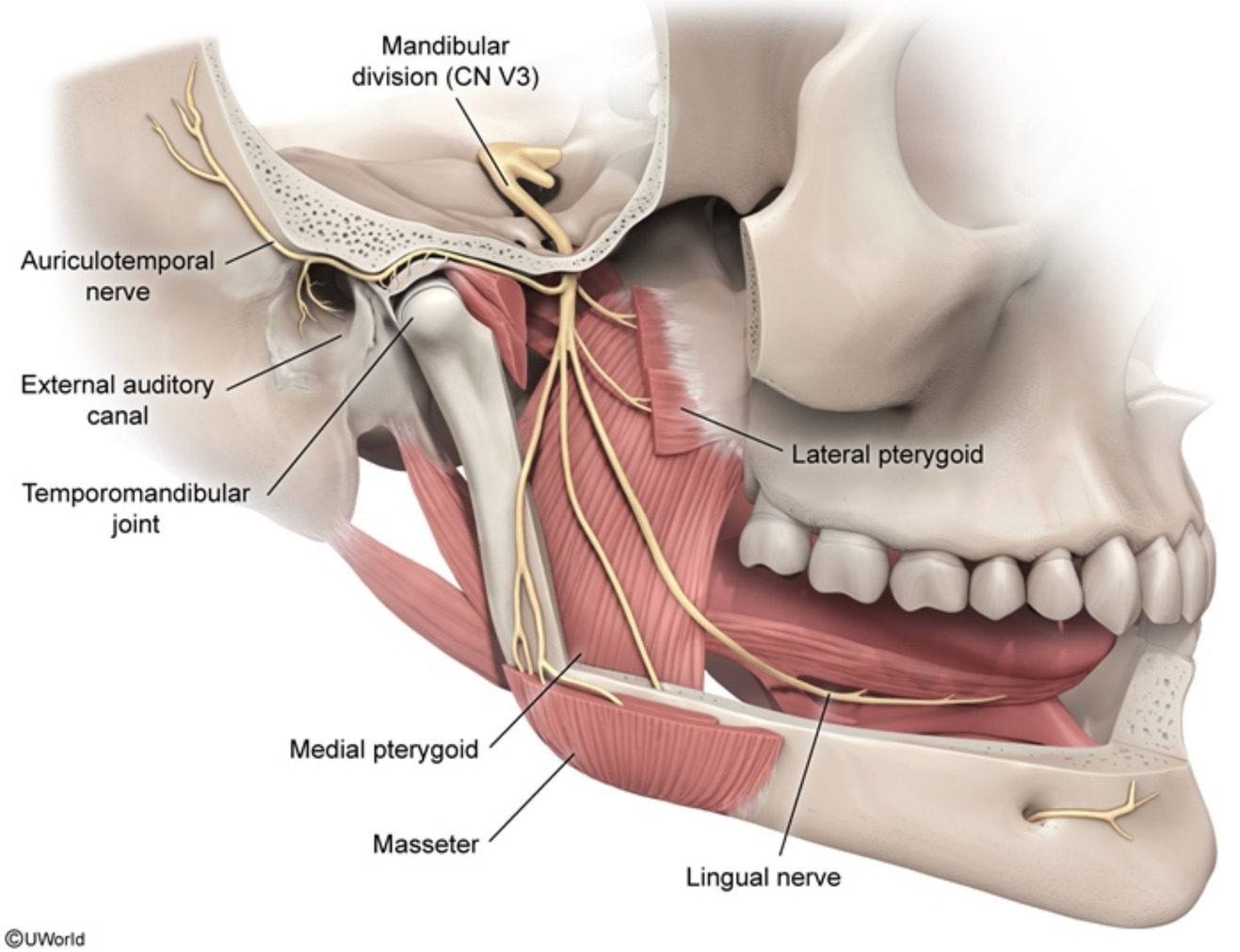


This patient's presentation is most consistent with **temporomandibular joint disorder** (TMD). The underlying etiology of TMD is multifactorial and includes temporomandibular joint derangement (eg, jaw misalignment, jaw clenching/teeth grinding, trauma) and hypersensitivity of the

©UWorld

This patient's presentation is most consistent with **temporomandibular joint disorder** (TMD). The underlying etiology of TMD is multifactorial and includes temporomandibular joint derangement (eg, jaw misalignment, jaw clenching/teeth grinding, trauma) and hypersensitivity of the mandibular nerve (CN V3). In addition to the classic symptoms of dull, waxing-and-waning face/jaw pain (worse with chewing) and clicking/popping noises with jaw movement, TMD can also present with ear-related symptoms (eg, ear pain, ear stuffiness, tinnitus).

Many of these clinical findings are due to involvement of the **mandibular nerve** (CN V3), which is the largest branch of the **trigeminal nerve**. It supplies sensation to the temporomandibular joint, floor of mouth, anterior tongue, and lower part of the face. In addition, it contributes to the sensory innervation of the **external auditory canal**; therefore, TMD can present with **ear pain** that is **referred** from the jaw joint. Ear stuffiness may be related to hypersensitivity affecting the tensor tympani. Theories regarding tinnitus in TMD include the proximity of the muscles of mastication to the ear and central connections between nerve supply of the temporomandibular joint and the areas of the brain involved in hearing.

**(Choice A)** The sensory component of the glossopharyngeal nerve (CN IX) carries general sensory information from the tonsils, pharynx, middle ear, and posterior third of the tongue; special sensory information (taste) from the posterior third of the tongue; and visceral sensory information from the carotid bodies and carotid sinus.

**(Choice B)** The hypoglossal nerve (CN XII) carries general motor efferent information to the intrinsic and extrinsic muscles of the tongue.

**(Choice D)** The auricular branch of the vagus nerve (CN X) conveys sensory information from the external auditory canal but is not thought to be involved in the pathogenesis of TMD.

**(Choice E)** The vestibulocochlear nerve (CN VIII) carries only special sensory information (auditory and balance) from the inner ear.

**Educational objective:**
Temporomandibular joint disorder is associated with derangement of the temporomandibular joint and hypersensitivity of the mandibular nerve (CN V3).

**References**

- Temporomandibular disorder: otologic implications and its relationship to sleep bruxism.
- Temporomandibular disorder: an underdiagnosed cause of headache, sinus pain, and ear pain.

A 48-year-old man comes to the office due to right inguinal discomfort. The patient first noticed "bumps" in his groin when he was dressing in the morning. He does not know how long they have been present but thinks they are relatively new. The patient was treated for gonorrhea several years ago but has no other medical problems. He drinks alcohol occasionally but does not use tobacco or illicit drugs. His mother died of metastatic melanoma. Cardiopulmonary examination is normal. The abdomen is soft and nontender. The right inguinal lymph nodes are enlarged and tender, as are several nodes in the right popliteal area. The distribution of lymphadenopathy in this patient would most likely be seen in which of the following conditions?

A. Asymmetric, hard prostate nodules

B. Firm, nontender right testicular mass

C. Large, irregular mole on the right great toe

D. Purulent laceration on the right lateral foot

E. Ulcerative lesion on the glans penis

Submit

A 48-year-old man comes to the office due to right inguinal discomfort. The patient first noticed "bumps" in his groin when he was dressing in the morning. He does not know how long they have been present but thinks they are relatively new. The patient was treated for gonorrhea several years ago but has no other medical problems. He drinks alcohol occasionally but does not use tobacco or illicit drugs. His mother died of metastatic melanoma. Cardiopulmonary examination is normal. The abdomen is soft and nontender. The right inguinal lymph nodes are enlarged and tender, as are several nodes in the right popliteal area. The distribution of lymphadenopathy in this patient would most likely be seen in which of the following conditions?

- A. Asymmetric, hard prostate nodules (4%)
- B. Firm, nontender right testicular mass (10%)
- C. Large, irregular mole on the right great toe (20%)
- ✓ D. Purulent laceration on the right lateral foot (43%)
- E. Ulcerative lesion on the glans penis (20%)

Omitted
Correct answer
D

43%
Answered correctly

03 secs
Time Spent

02/28/2020
Last Updated

Explanation

# Lymphatic drainage of the lower extremity

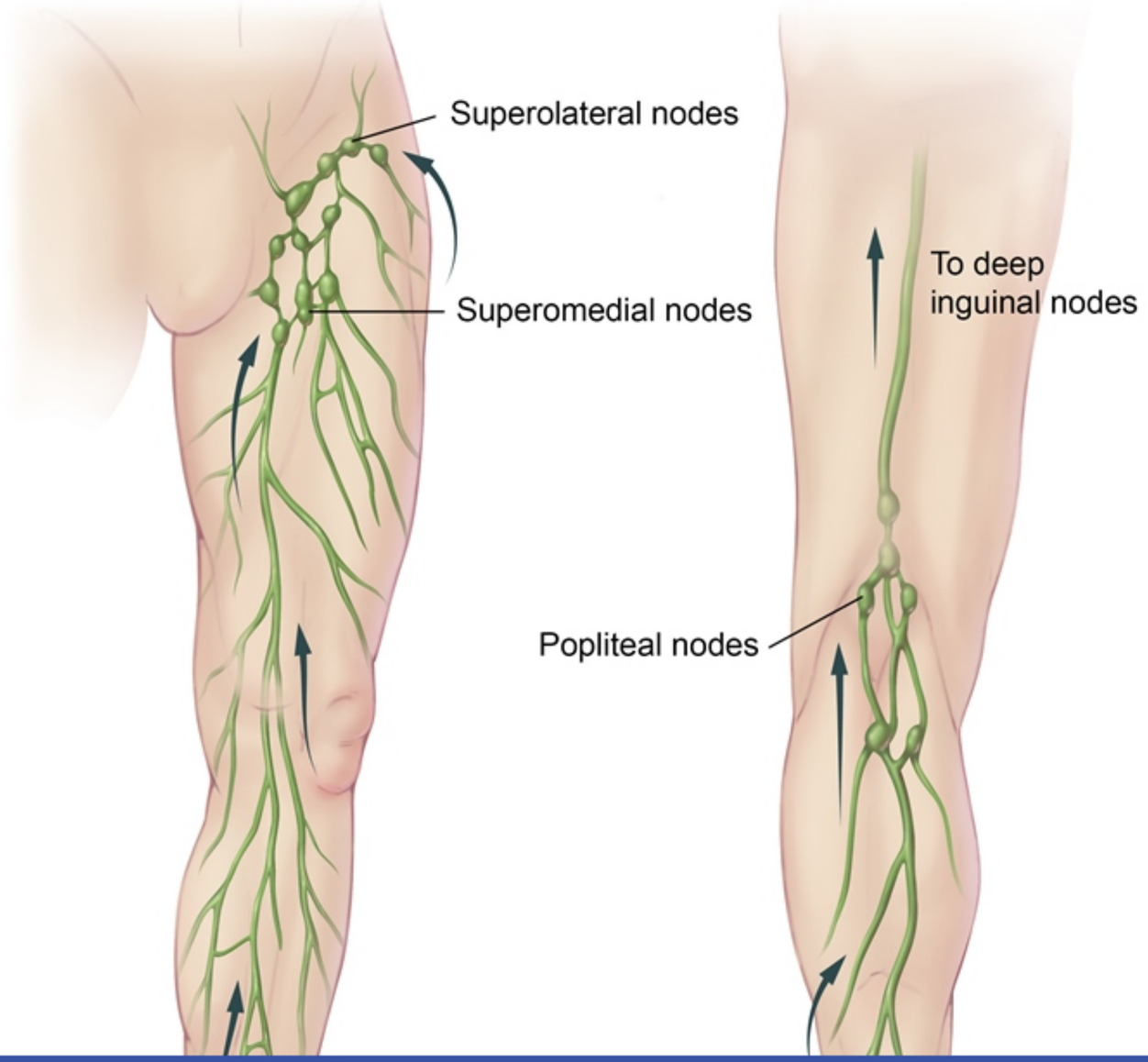

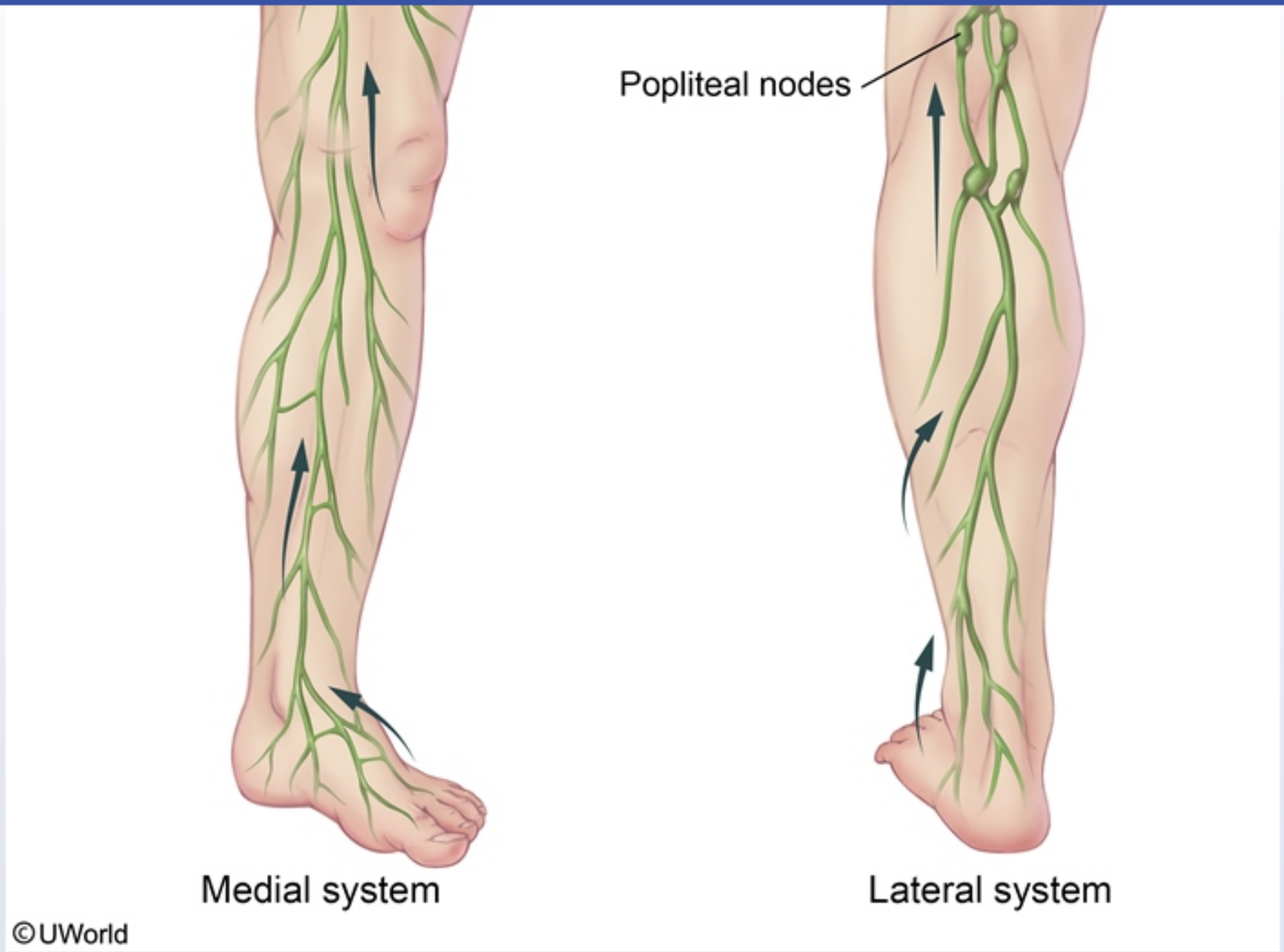


The **lymphatic system** of the extremities is divided into the superficial lymphatic vessels, which follow the venous system, and the deep lymphatic vessels, which follow the arterial system. The superficial vessels receive lymph from the skin and subcutaneous tissues, whereas the deep vessels drain both the deep muscles and the superficial vessels.

In the **lower extremities**, the superficial lymphatic system is divided into medial and **lateral tracks**. The medial track runs along the long

The **lymphatic system** of the extremities is divided into the superficial lymphatic vessels, which follow the venous system, and the deep lymphatic vessels, which follow the arterial system. The superficial vessels receive lymph from the skin and subcutaneous tissues, whereas the deep vessels drain both the deep muscles and the superficial vessels.

In the **lower extremities**, the superficial lymphatic system is divided into medial and **lateral tracks**. The medial track runs along the long saphenous vein up to the superficial inguinal lymph nodes, bypassing the popliteal nodes. Consequently, lesions on the medial foot cause inguinal lymphadenopathy **(Choice C)**. In contrast, lateral lesions, which drain via the lateral track and communicate with the popliteal and inguinal nodes, are more likely to cause lymphadenopathy in both the **popliteal and inguinal** areas.

**(Choice A)** Lymph from the prostate drains primarily into the internal iliac lymph nodes.

**(Choice B)** Lymph from the scrotum is drained into the superficial inguinal lymph nodes, and lymphatic vessels from the testes mirror the testicular arteries and drain into the para-aortic lymph nodes.

**(Choice E)** In addition to receiving drainage from the lower extremity, the superficial inguinal lymph nodes receive drainage from the scrotum (not testes), perineum, anterior abdominal wall (inferior to the umbilicus), buttocks, and skin of the penis. In contrast, the glans penis and penile urethra drain primarily via the deep lymphatic system into the deep inguinal nodes. The popliteal nodes would not be affected by a lesion on the glans.

**Educational objective:**
In the lower extremities, the superficial lymphatic system is divided into medial and lateral tracks. The medial track runs up to the superficial inguinal lymph nodes, bypassing the popliteal nodes. Consequently, lesions on the medial foot cause inguinal lymphadenopathy, whereas lateral lesions are more likely to cause lymphadenopathy in both the popliteal and inguinal areas.

**References**

- Lymphoedema of the lower extremities—background, pathophysiology and diagnostic considerations.

| Anatomy | General Principles | Lymphatic drainage |
|---|---|---|
| Subject | System | Topic |

Copyright © UWorld. All rights reserved.

The **lymphatic system** of the extremities is divided into the superficial lymphatic vessels, which follow the venous system, and the deep lymphatic

**Exhibit Display**

Lymph vessels & nodes of male genitalia

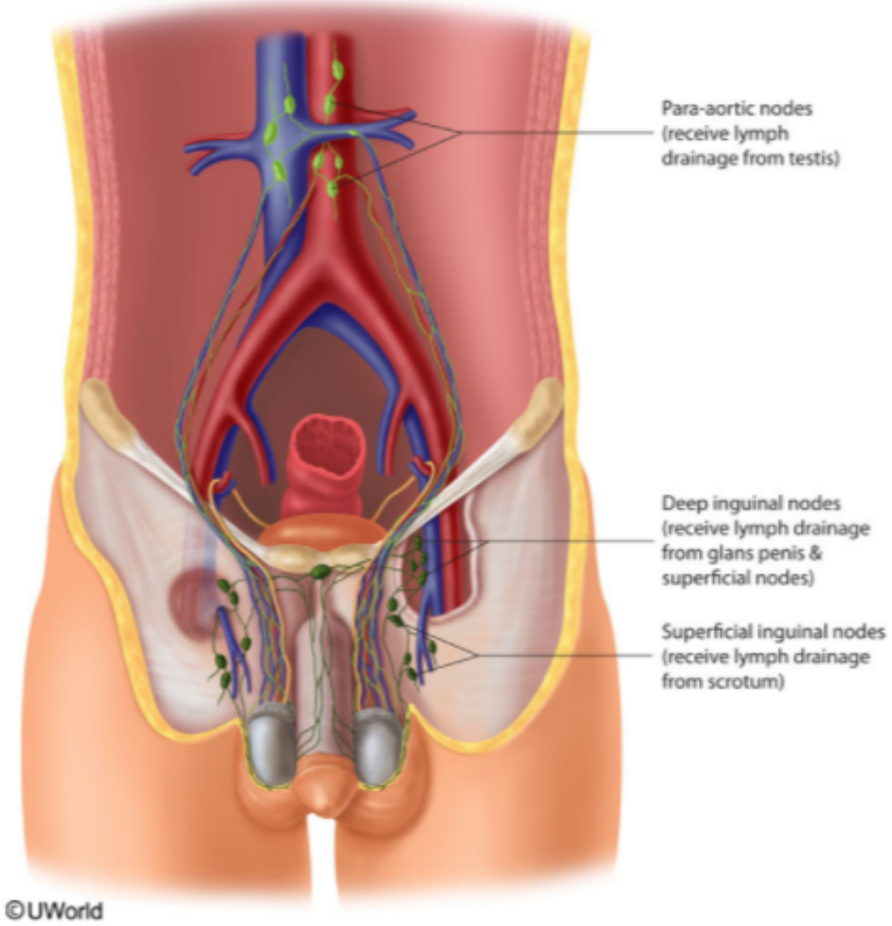


Zoom In | Zoom Out | Reset | Add To New Card | Existing Card

Copyright © UWorld. All rights reserved.

A 26-year-old woman is evaluated in the clinic due to absence of her last 3 menstrual periods. The patient has also developed bilateral milky nipple discharge. Menarche was at age 13. Until now, she has had regular menses, lasting 4-5 days, every 28 days. The patient says she takes acetaminophen for occasional headaches and a medication that "stops the voices" in her head. BMI is 29 kg/m$^2$. Pelvic examination is unremarkable. Urine β-hCG testing is negative. Interruption of which of the following central nervous system pathways is the most likely cause of this patient's presenting symptoms?

A. Arcuate fasciculus

B. Hypothalamospinal tract

C. Lateral medullary spinothalamic tract

D. Mesolimbic pathway

E. Nigrostriatal pathway

F. Tuberoinfundibular pathway

Submit

A 26-year-old woman is evaluated in the clinic due to absence of her last 3 menstrual periods. The patient has also developed bilateral milky nipple discharge. Menarche was at age 13. Until now, she has had regular menses, lasting 4-5 days, every 28 days. The patient says she takes acetaminophen for occasional headaches and a medication that "stops the voices" in her head. BMI is 29 kg/m$^2$. Pelvic examination is unremarkable. Urine β-hCG testing is negative. Interruption of which of the following central nervous system pathways is the most likely cause of this patient's presenting symptoms?

- A. Arcuate fasciculus (1%)
- B. Hypothalamospinal tract (8%)
- C. Lateral medullary spinothalamic tract (0%)
- D. Mesolimbic pathway (9%)
- E. Nigrostriatal pathway (12%)
- ✓ F. Tuberoinfundibular pathway (67%)

Omitted
Correct answer
F

67%
Answered correctly

02 secs
Time Spent

01/28/2020
Last Updated

Explanation

**Prolactin**

# Prolactin

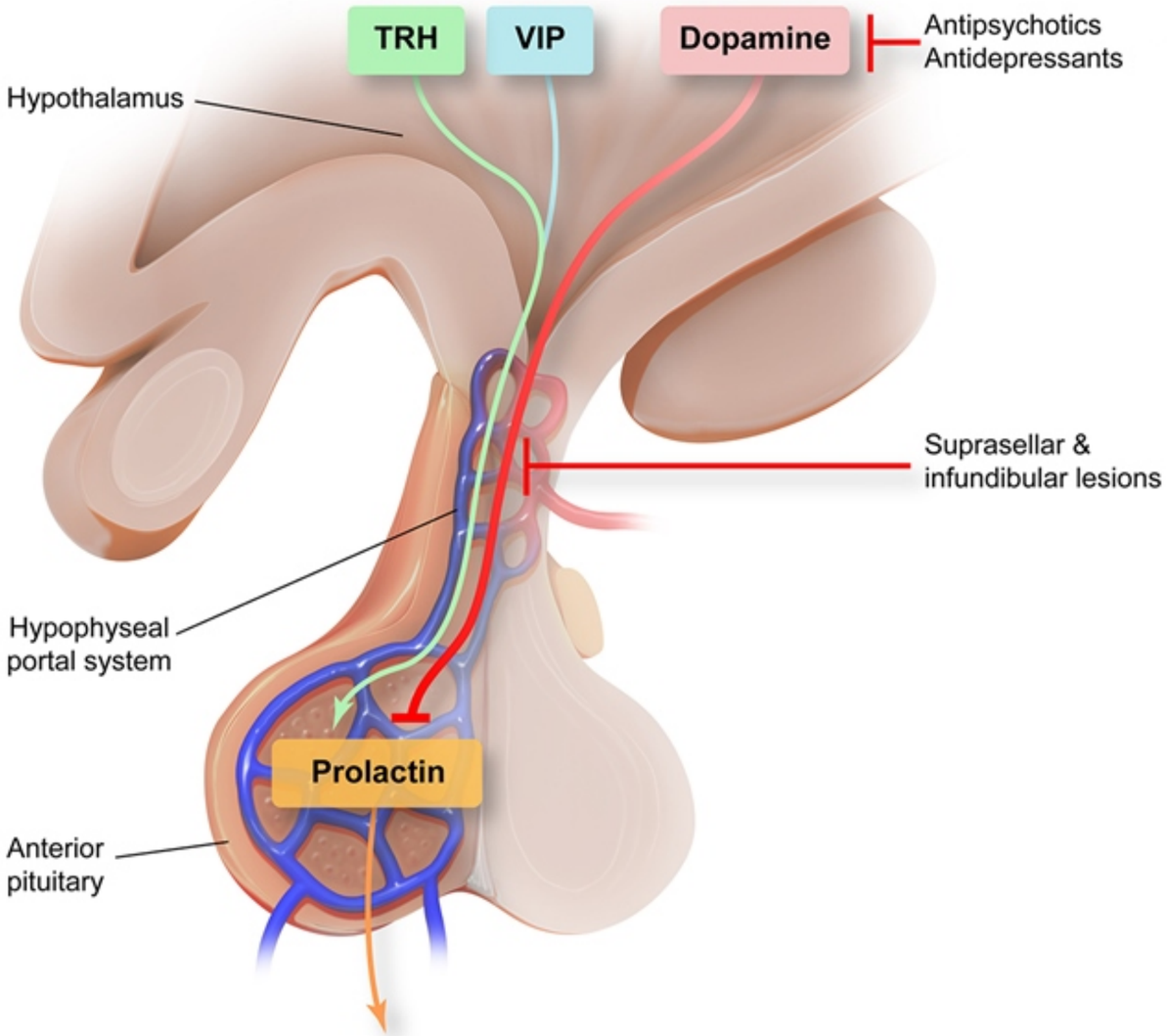
TRH
VIP
Dopamine
Antipsychotics
Antidepressants
Hypothalamus
Suprasellar &
infundibular lesions
Hypophyseal
portal system
Prolactin
Anterior
pituitary

**Systemic circulation**

**TRH** = thyrotropin-releasing hormone; **VIP** = vasoactive intestinal peptide.

©UWorld

This patient likely has developed amenorrhea and galactorrhea as an adverse effect of dopamine-2 (D2) receptor blockade from treatment with antipsychotics. There are 4 major dopaminergic pathways in the brain (eg, mesolimbic, mesocortical, tuberoinfundibular, nigrostriatal); dopamine hyperactivity in the mesolimbic pathway is associated with positive psychotic symptoms (eg hallucinations, delusions).

The side effects of antipsychotic therapy are largely caused by D2 receptor blockade in other dopaminergic pathways. The **tuberoinfundibular pathway** connects the hypothalamus to the pituitary gland and is responsible for the tonic inhibition of prolactin secretion. Neurons in the arcuate nucleus of the hypothalamus secrete dopamine, which binds to D2 receptors on pituitary lactotrophs, resulting in decreased prolactin secretion from the anterior pituitary gland. Antipsychotics can interrupt the tuberoinfundibular pathway, causing increased blood prolactin levels **(hyperprolactinemia)**, which may lead to **galactorrhea** (milky nipple discharge unrelated to pregnancy/breastfeeding) and menstrual irregularities (eg, **amenorrhea**).

**(Choice A)** The arcuate fasciculus is a neural pathway that connects the Broca and Wernicke areas, which are responsible for expressive and receptive language, respectively. Disruption of the arcuate fasciculus classically results in conduction aphasia, characterized by fluent speech, intact comprehension, and impaired repetition.

**(Choice B)** The hypothalamospinal tract projects from the hypothalamus to the ciliospinal center of the intermediolateral cell column (T1-L2), providing sympathetic innervation to the ipsilateral eye and face. Disruption of this tract typically results in ipsilateral Horner syndrome (eg, ptosis, miosis, anhidrosis).

**(Choice C)** The lateral medullary spinothalamic tract transmits pain and temperature signals from the contralateral body to the thalamus. Lateral medullary infarction (Wallenberg syndrome) presents with loss of pain and temperature sensation on the contralateral body and ipsilateral face as well as vertigo, hoarseness, dysphagia, and abnormal eye movements.

**(Choice D)** The therapeutic effect of antipsychotics arises from blockade D2 receptors in the mesolimbic pathway.

**(Choice E)** The nigrostriatal pathway projects from the substantia nigra to the caudate nucleus and putamen and primarily regulates the coordination of voluntary movements. D2 receptor blockade in this pathway results in extrapyramidal effects (eg, dystonia, akathisia, tardive dyskinesia) and drug-induced parkinsonism.

**(Choice A)** The arcuate fasciculus is a neural pathway that connects the Broca and Wernicke areas, which are responsible for expressive and receptive language, respectively. Disruption of the arcuate fasciculus classically results in conduction aphasia, characterized by fluent speech, intact comprehension, and impaired repetition.

**(Choice B)** The hypothalamospinal tract projects from the hypothalamus to the ciliospinal center of the intermediolateral cell column (T1-L2), providing sympathetic innervation to the ipsilateral eye and face. Disruption of this tract typically results in ipsilateral Horner syndrome (eg, ptosis, miosis, anhidrosis).

**(Choice C)** The lateral medullary spinothalamic tract transmits pain and temperature signals from the contralateral body to the thalamus. Lateral medullary infarction (Wallenberg syndrome) presents with loss of pain and temperature sensation on the contralateral body and ipsilateral face as well as vertigo, hoarseness, dysphagia, and abnormal eye movements.

**(Choice D)** The therapeutic effect of antipsychotics arises from blockade D2 receptors in the mesolimbic pathway.

**(Choice E)** The nigrostriatal pathway projects from the substantia nigra to the caudate nucleus and putamen and primarily regulates the coordination of voluntary movements. D2 receptor blockade in this pathway results in extrapyramidal effects (eg, dystonia, akathisia, tardive dyskinesia) and drug-induced parkinsonism.

**Educational objective:**
Antipsychotic medications work by blocking dopamine-2 receptors in the mesolimbic dopamine pathway. Dopamine-2 receptor blockade in the tuberoinfundibular pathway can result in galactorrhea and amenorrhea.

**References**

- A real-world analysis of healthcare costs and relative risk of hyperprolactinemia associated with antipsychotic treatments in the United States.
- The effects of antipsychotics on prolactin levels and women's menstruation.

| Anatomy | Psychiatric/Behavioral & Substance Abuse | Antipsychotics |
|---|---|---|
| Subject | System | Topic |

Copyright © UWorld. All rights reserved.

Exhibit Display

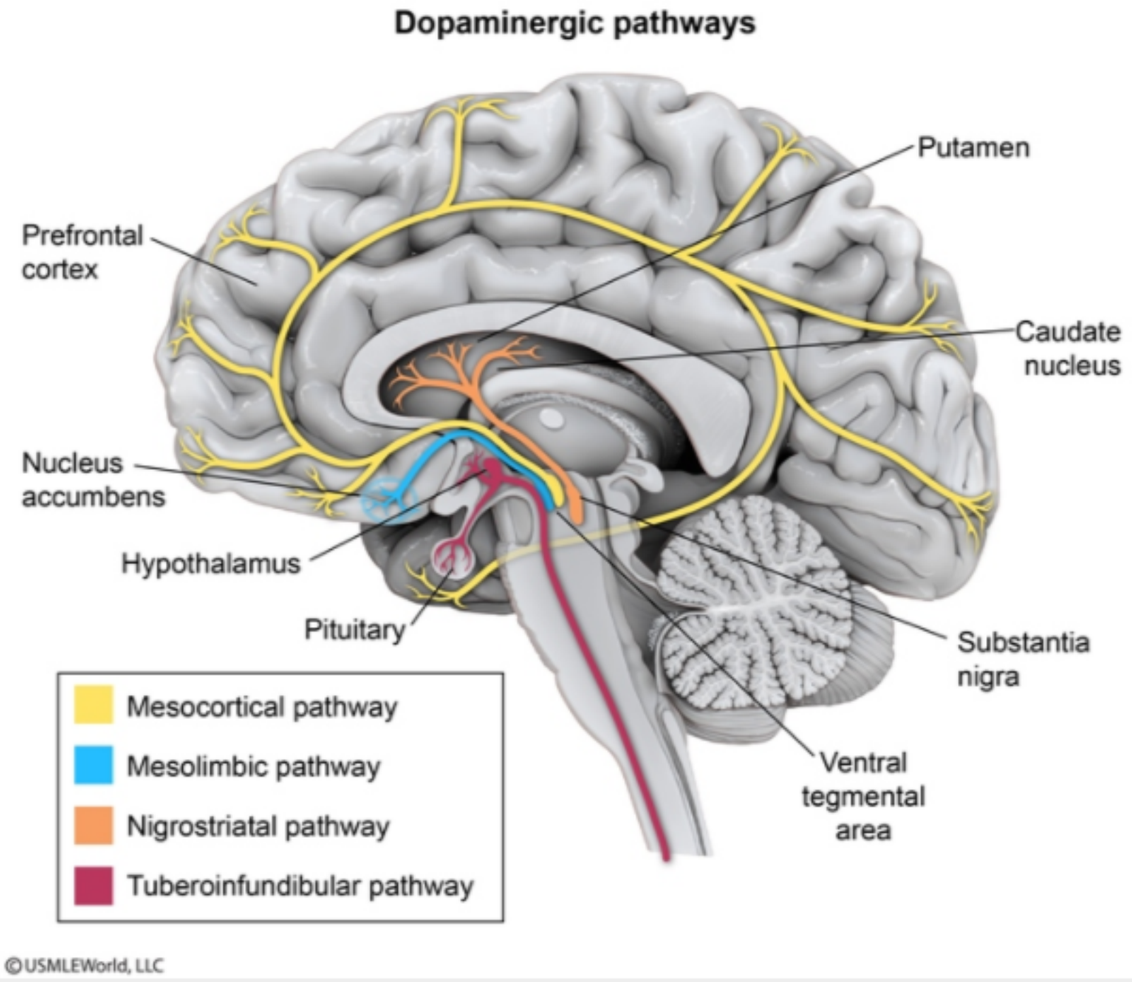


Zoom In | Zoom Out | Reset | Add To New Card | Existing Card

coordination of voluntary movements. D2 receptor blockade in this pathway results in extrapyramidal effects (eg, dystonia, akathisia, tardive

A 44-year-old man comes to the office for evaluation of a neck lump. The patient first noticed the lump 6 months ago while he was shaving and says that it seems to be growing in size. He has no pain, shortness of breath, cough, hoarseness, or difficulty swallowing. The patient had Hodgkin lymphoma 20 years ago, which was successfully treated with radiation therapy to his chest and neck. Physical examination shows a firm mass in the left thyroid lobe. There is no lymphadenopathy. Serum TSH level is normal. Fine-needle aspiration biopsy reveals papillary thyroid cancer. A total thyroidectomy is performed. During an attempt to ligate the inferior thyroid artery, a nervous structure in close proximity is inadvertently damaged. Which of the following was most likely injured during the surgery?

- A. Accessory nerve
- B. Ansa cervicalis
- C. Hypoglossal nerve
- D. Phrenic nerve
- E. Recurrent laryngeal nerve
- F. Superior cervical ganglion
- G. Superior laryngeal nerve

Submit

A 44-year-old man comes to the office for evaluation of a neck lump. The patient first noticed the lump 6 months ago while he was shaving and says that it seems to be growing in size. He has no pain, shortness of breath, cough, hoarseness, or difficulty swallowing. The patient had Hodgkin lymphoma 20 years ago, which was successfully treated with radiation therapy to his chest and neck. Physical examination shows a firm mass in the left thyroid lobe. There is no lymphadenopathy. Serum TSH level is normal. Fine-needle aspiration biopsy reveals papillary thyroid cancer. A total thyroidectomy is performed. During an attempt to ligate the inferior thyroid artery, a nervous structure in close proximity is inadvertently damaged. Which of the following was most likely injured during the surgery?

- A. Accessory nerve (0%)
- B. Ansa cervicalis (2%)
- C. Hypoglossal nerve (0%)
- D. Phrenic nerve (1%)
- ✓ E. Recurrent laryngeal nerve (81%)
- F. Superior cervical ganglion (0%)
- G. Superior laryngeal nerve (13%)

Omitted
Correct answer
E

81%
Answered correctly

02 secs
Time Spent

04/06/2020
Last Updated

Explanation

1
2
3
4
5
6
7
8
9
10
11
12
13
14
15
16
17

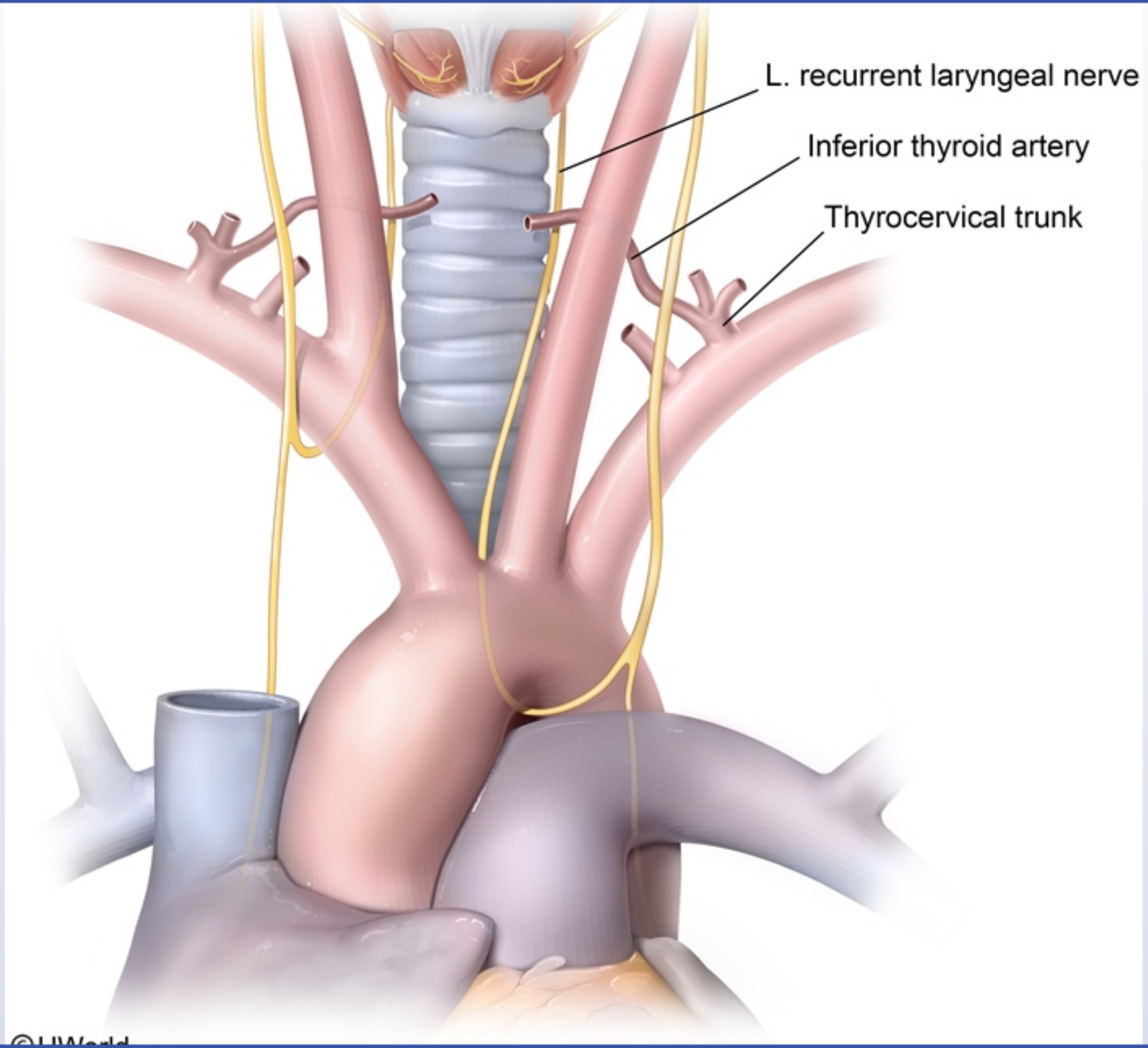


©UWorld

©UWorld

The **inferior thyroid artery** arises from the thyrocervical trunk, a branch of the subclavian artery. Along with the superior thyroid arteries (branches of the external carotid arteries), the inferior thyroid arteries provide blood to the thyroid gland and other structures of the anterior neck. From the thyrocervical trunk, the inferior thyroid artery courses deep to the internal jugular vein, vagus nerve, and common carotid artery before turning toward the thyroid. As it approaches the thyroid, the artery comes in **close proximity** to the **recurrent laryngeal nerve**.

The recurrent laryngeal nerve is a branch of the vagus nerve that loops below the aortic arch on the left and below the subclavian artery on the right to provide motor innervation to the intrinsic muscles of the larynx (except the cricothyroid). During **thyroid surgery**, this nerve may be **damaged** due to its proximity to the inferior thyroid artery. Unilateral nerve injury often causes **hoarseness**, whereas bilateral injury may cause inspiratory stridor and respiratory distress due to complete **vocal cord paralysis**.

**(Choice A)** The spinal accessory nerve (CN XI) exits the jugular foramen and courses on top of the levator scapulae muscle to innervate the sternocleidomastoid and trapezius muscles on either side.

**(Choice B)** The ansa cervicalis is a loop of the cervical plexus that receives contributions from C1-C3. It courses deep to the sternocleidomastoid muscle and loops around the internal jugular vein. Branches from the ansa cervicalis innervate the sternohyoid, sternothyroid, and omohyoid muscles.

**(Choice C)** The hypoglossal nerve (CN XII) exits the cranium through the hypoglossal canal and innervates all the muscles of the tongue except the palatoglossus.

**(Choice D)** The phrenic nerve arises from the C3-C5 cervical nerves and innervates the diaphragm. The most common cause of iatrogenic phrenic nerve injury is cardiothoracic surgery, in which the nerve can be damaged where it passes between the pericardium and mediastinal pleura. Manifestations include diaphragmatic paralysis (inspiratory weakness).

**(Choice F)** The superior cervical ganglion is part of the sympathetic nervous system. It can be injured by an expanding lung cancer at the superior pulmonary sulcus (Pancoast tumor), leading to Horner syndrome (ie, ipsilateral ptosis, miosis, and anhydrosis).

**(Choice G)** The superior laryngeal nerve branches off the vagus nerve high in the neck and divides into an external branch, which supplies the cricothyroid muscle, and an internal branch, which provides sensation over the supraglottic area. The external branch of this nerve may be misligated during thyroid surgery due to its proximity to the superior thyroid artery.

**(Choice B)** The ansa cervicalis is a loop of the cervical plexus that receives contributions from C1-C3. It courses deep to the sternocleidomastoid muscle and loops around the internal jugular vein. Branches from the ansa cervicalis innervate the sternohyoid, sternothyroid, and omohyoid muscles.

**(Choice C)** The hypoglossal nerve (CN XII) exits the cranium through the hypoglossal canal and innervates all the muscles of the tongue except the palatoglossus.

**(Choice D)** The phrenic nerve arises from the C3-C5 cervical nerves and innervates the diaphragm. The most common cause of iatrogenic phrenic nerve injury is cardiothoracic surgery, in which the nerve can be damaged where it passes between the pericardium and mediastinal pleura. Manifestations include diaphragmatic paralysis (inspiratory weakness).

**(Choice F)** The superior cervical ganglion is part of the sympathetic nervous system. It can be injured by an expanding lung cancer at the superior pulmonary sulcus (Pancoast tumor), leading to Horner syndrome (ie, ipsilateral ptosis, miosis, and anhydrosis).

**(Choice G)** The superior laryngeal nerve branches off the vagus nerve high in the neck and divides into an external branch, which supplies the cricothyroid muscle, and an internal branch, which provides sensation over the supraglottic area. The external branch of this nerve may be misligated during thyroid surgery due to its proximity to the superior thyroid artery.

**Educational objective:**
The recurrent laryngeal nerve travels in close proximity to the inferior thyroid artery and can be injured during thyroid surgery, resulting in vocal cord paralysis (eg, hoarseness).

**References**

- Anatomical relationship between recurrent laryngeal nerve and inferior thyroid artery in thyroidectomy patients.
- An applied anatomical study on the recurrent laryngeal nerve and inferior thyroid artery.

| Anatomy | Ear, Nose & Throat (ENT) | Thyroid cancer |
|---|---|---|
| Subject | System | Topic |

Copyright © UWorld. All rights reserved.

A 30-year-old man comes to the emergency department due to left eye pain after being involved in a street fight. He received a fist blow to the left eye and has since had pain and diplopia. Past medical history is notable for 2 previous gunshot wounds. The patient does not smoke cigarettes but has a history of heavy alcohol intake and frequent marijuana use. On examination, there is significant soft tissue swelling around the left eye. Visual acuity is normal, but extraocular motility of the left eye is limited. Pupillary reflexes are normal. Coronal CT scan of the orbits is shown in the image below.

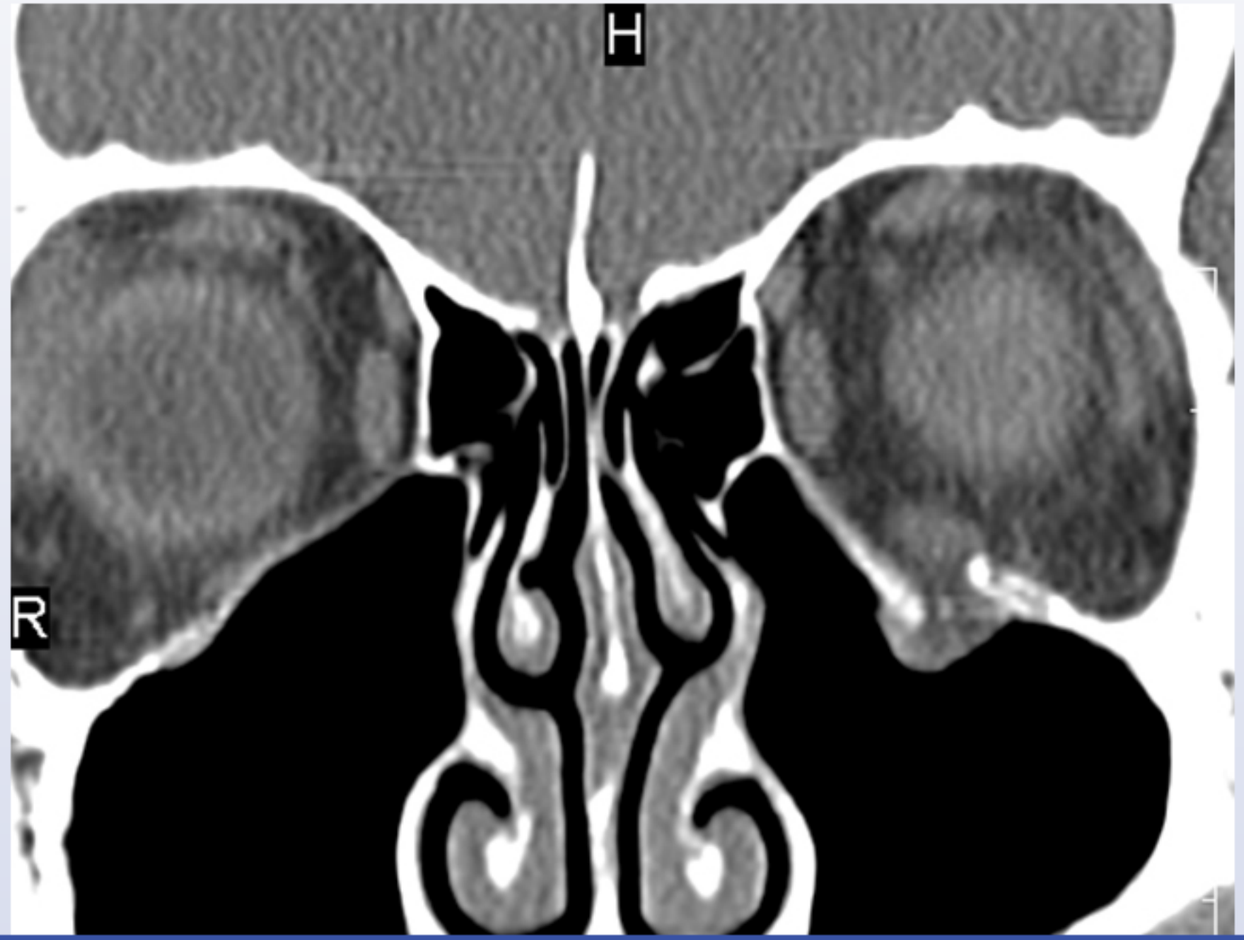

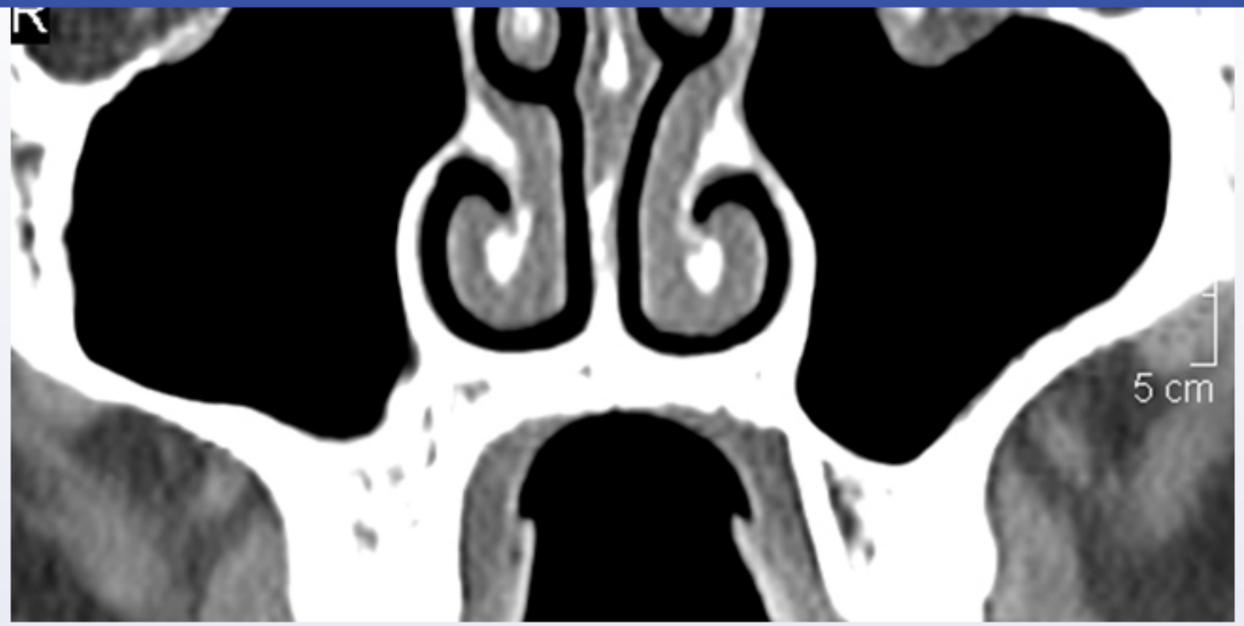


The orbital contents of this patient are most likely to herniate into which of the following sites?

- A. Ethmoid cells
- B. Frontal sinus
- C. Inferior conchae
- D. Maxillary sinus
- E. Sphenoid sinus

Submit

1
2
3
4
5
6
7
8
9
10
11
12
13
14
15
16
17

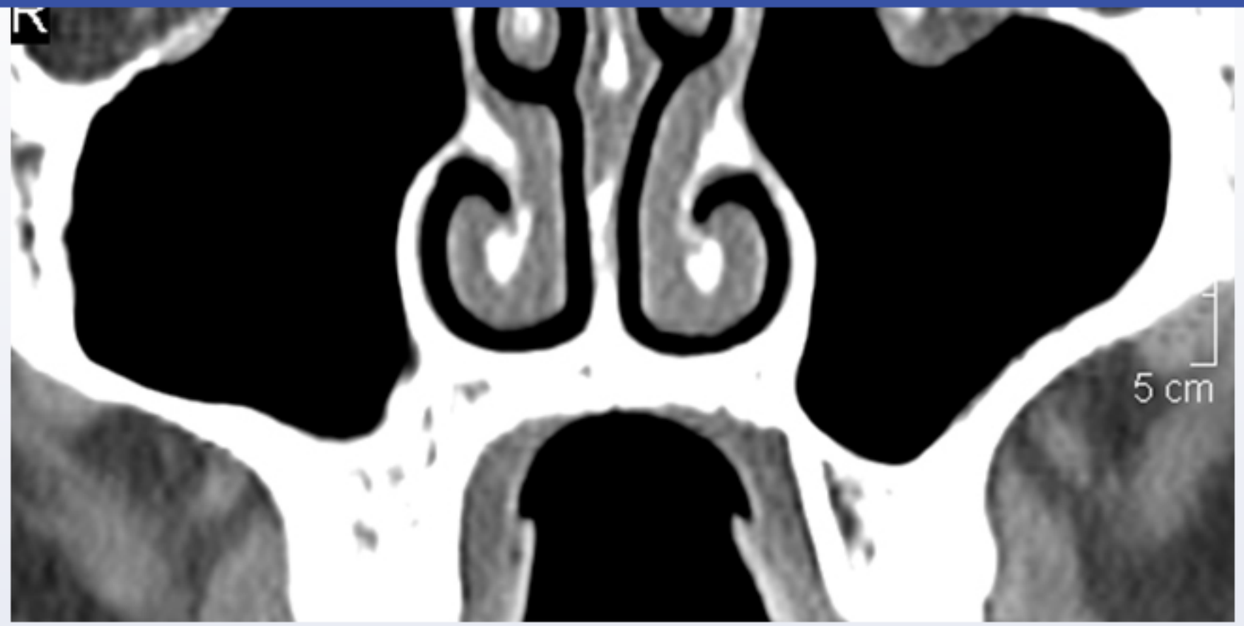


The orbital contents of this patient are most likely to herniate into which of the following sites?

A. Ethmoid cells (4%)
B. Frontal sinus (2%)
C. Inferior conchae (0%)
✓ D. Maxillary sinus (85%)
E. Sphenoid sinus (6%)

Omitted
Correct answer

85%
Answered correctly

09 secs
Time Spent

05/05/2020
Last Updated

Omitted
Correct answer
D

85%
Answered correctly

09 secs
Time Spent

05/05/2020
Last Updated

## Explanation

The orbit is bound superiorly by the thick orbital plate of the frontal bone and laterally by the thick bone of the zygoma and greater and lesser sphenoid wings. In contrast, the **orbital floor** is composed of a very thin layer of bone that separates the orbit from the air-filled **maxillary sinus**. Similarly, the orbit's medial wall is composed of the thin ethmoid and lacrimal bones, which separate it from the ethmoid air cells.

Blunt trauma to the eye causes a rapid increase in pressure that typically does not rupture the globe but is transmitted posteriorly into the orbit. The weakest plates of bone in the orbit, the medial and inferior walls, are common sites of fracture. Fracture is typically evident on radiographic imaging, and fluid (eg, blood) or herniation of the orbital contents can often be visualized in the adjacent normally air-filled sinuses.

**(Choice A)** The ethmoid air cells are medial to the orbit. They are unaffected in this patient, but they can be affected in blowout fractures of the orbit's medial wall.

**(Choice B)** The frontal sinus is not pictured above. It lies in the medial part of the supraorbital frontal bone.

**(Choice C)** The inferior nasal conchae form part of the nasal turbinate system. They are not air-filled sinuses.

**(Choice E)** The sphenoid sinuses (not pictured above) lie anterior to the optic chiasm and are not in close relation to the orbit.

**Educational objective:**
Blunt trauma to the globe can cause orbital blowout fractures. These fractures most commonly involve the medial or inferior orbital walls due to the thin bone bordering the ethmoid and maxillary sinuses.

| Anatomy | Ear, Nose & Throat (ENT) | Orbital fracture |
|---|---|---|
| Subject | System | Topic |

Copyright © UWorld. All rights reserved.

Omitted
Correct answer

85%

09 secs

05/05/2020

## Exhibit Display

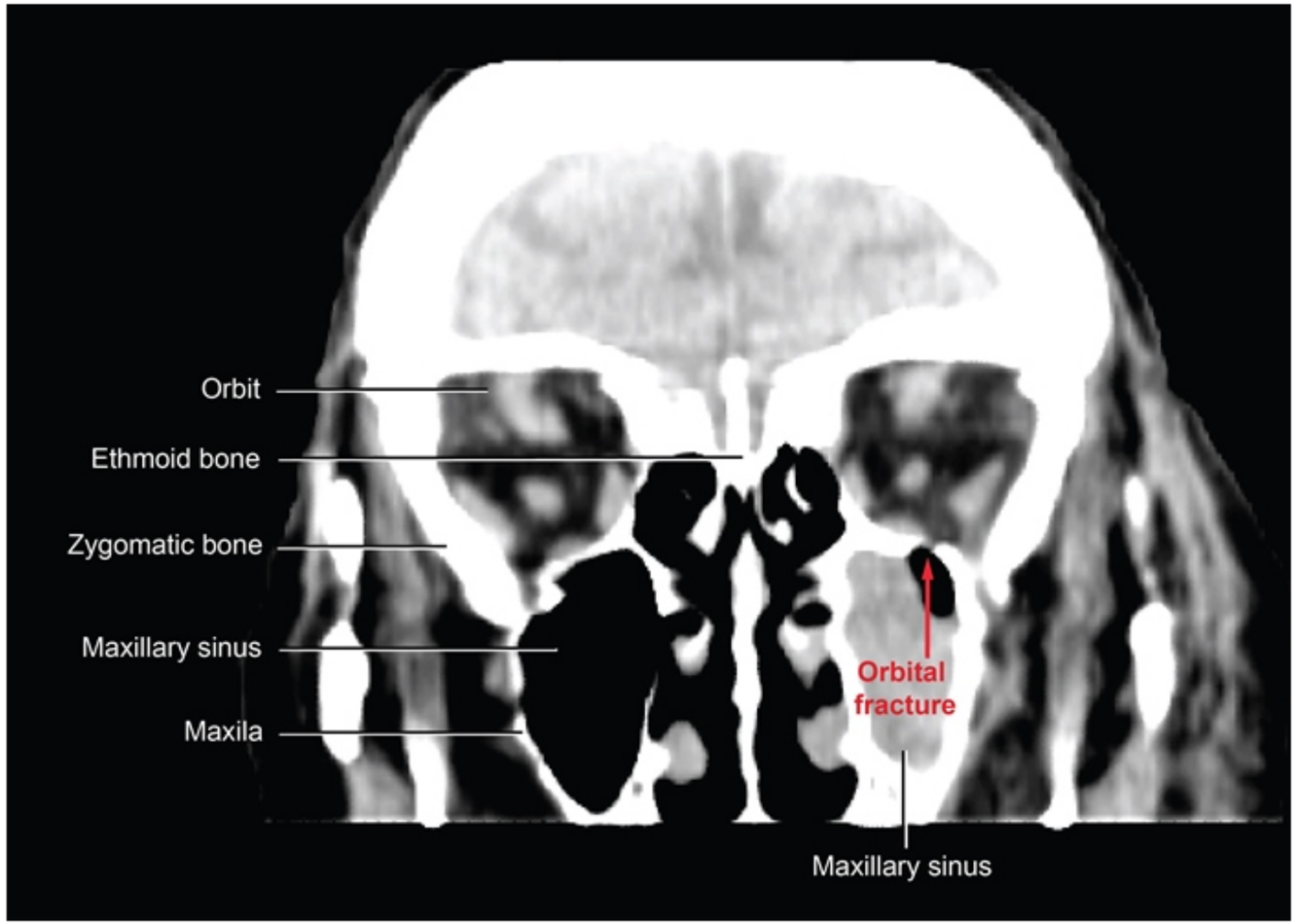


Zoom In | Zoom Out | Reset | Add To New Card | Existing Card

A 34-year-old woman comes to the physician complaining of double vision. She first experienced difficulty focusing her eyes while at work yesterday. Upon waking up this morning, her symptoms had progressed to frank diplopia. Her past medical history is insignificant. A complete physical examination is performed, including a full neurologic assessment. Shining light into her right eye causes constriction of her right pupil, but not the left pupil. Shining light into her left eye causes constriction of only her right pupil. Which of the following additional physical examination findings is likely to be found in this patient?

A. Absence of the left corneal reflex

B. Drooping of the left eyelid

C. Inability to close the left eye

D. Inward deviation of the left eye

E. Visual loss in the left eye

Submit

A 34-year-old woman comes to the physician complaining of double vision. She first experienced difficulty focusing her eyes while at work yesterday. Upon waking up this morning, her symptoms had progressed to frank diplopia. Her past medical history is insignificant. A complete physical examination is performed, including a full neurologic assessment. Shining light into her right eye causes constriction of her right pupil, but not the left pupil. Shining light into her left eye causes constriction of only her right pupil. Which of the following additional physical examination findings is likely to be found in this patient?

- A. Absence of the left corneal reflex (17%)
- ✓ B. Drooping of the left eyelid (60%)
- C. Inability to close the left eye (3%)
- D. Inward deviation of the left eye (10%)
- E. Visual loss in the left eye (8%)

Omitted
Correct answer
B

60%
Answered correctly

02 secs
Time Spent

06/14/2020
Last Updated

Explanation

**Pupillary light reflex**

1
2
3
4
5
6
7
8
9
10
11
12
13
14
15
16
17

Explanation

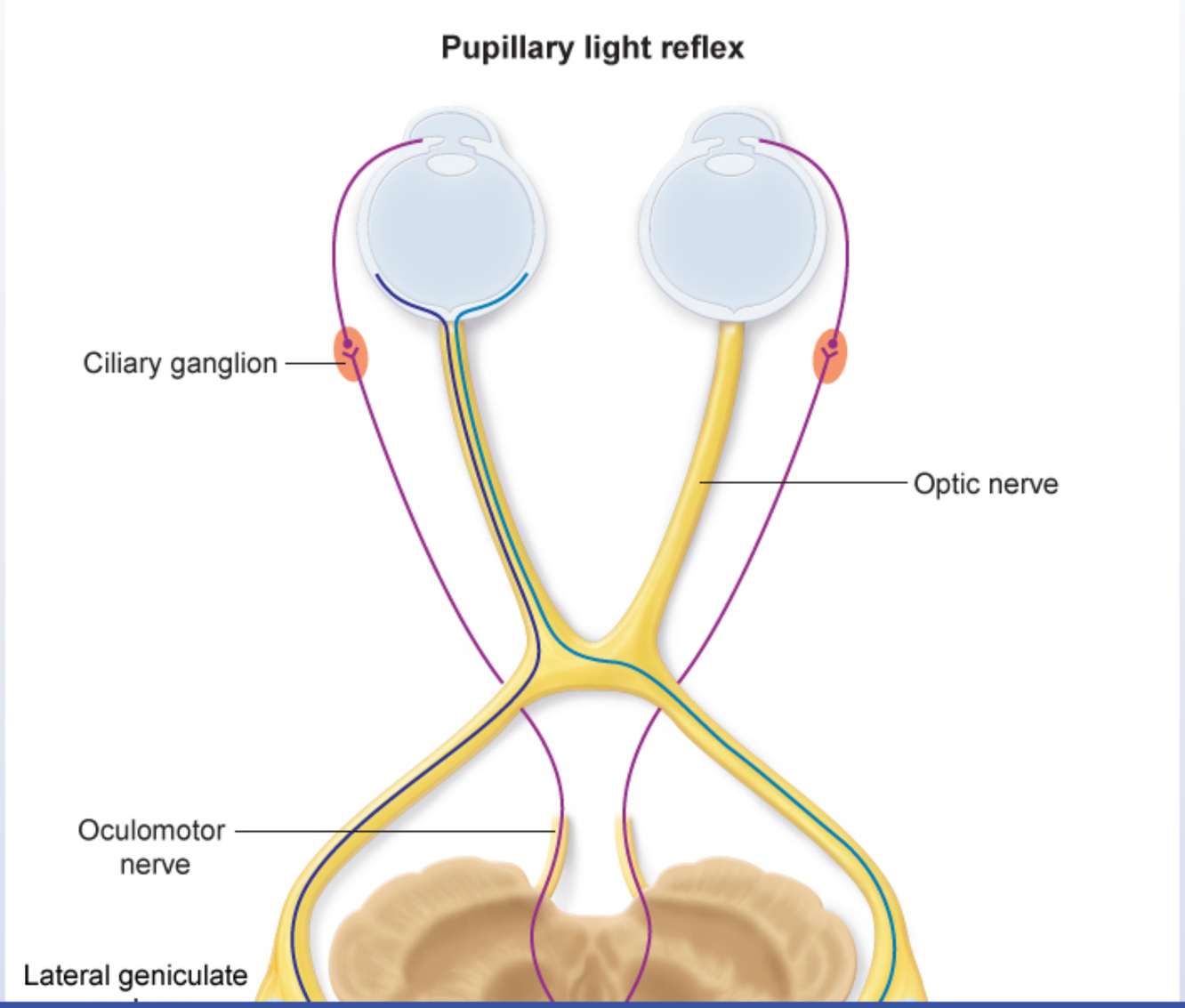

## Exhibit Display

### Pupillary light reflex

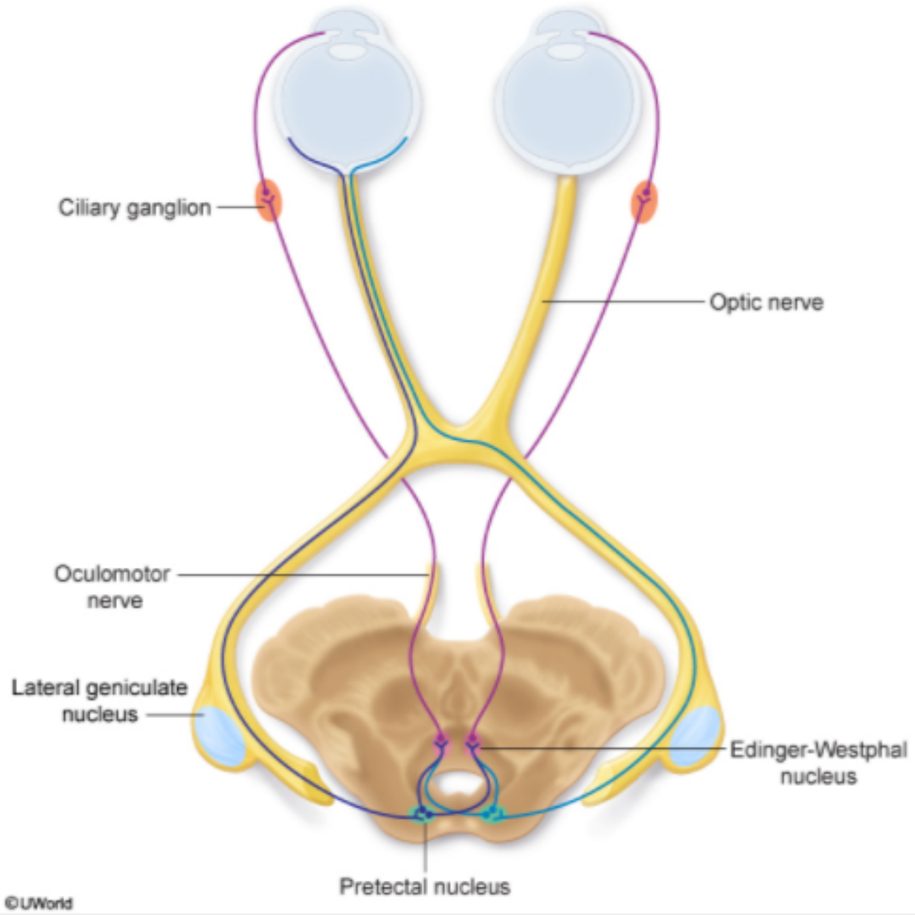


Zoom In | Zoom Out | Reset | Add To New Card | Existing Card

The pupillary light reflex is assessed by shining light in an eye and observing the response in that eye (direct) as well as the opposite eye (consensual). The optic nerve (CN II) is responsible for the afferent limb of this reflex; the oculomotor nerve (CN III) is responsible for the efferent limb. In this patient, the right CN II and right CN III are functional as there was a direct response seen when light was shined into the right eye. In addition, the left CN II is also functional as a consensual response occurred when light was shined into the left eye. However, constriction of the left pupil was not seen in either circumstance. Thus, this patient's lesion most likely involves her left CN III.

The symptoms of CN III palsy relate to the function of CN III:

1. A somatic component innervates the inferior, superior, and medial rectus; inferior oblique; and levator palpebrae muscles. Ptosis occurs due to paralysis of the levator palpebrae, and the unopposed action of the lateral rectus (CN VI) and superior oblique (CN IV) muscles leads to a "down-and-out" gaze.
2. Parasympathetic fibers of CN III innervate the iris sphincter and ciliary muscle. Paralysis of these fibers causes a fixed, dilated pupil and loss of accommodation.

CN III palsy can result from lesions anywhere along the nerve's path from the oculomotor nucleus in the midbrain to the extraocular muscles within the orbit. The most dreaded cause of isolated acute third nerve palsy is an actively enlarging intracranial aneurysm (at risk of imminent rupture).

**(Choice A)** Absence of the corneal reflex can result from lesions involving CN $V_1$ (afferent limb) or CN VII (efferent limb).

**(Choice C)** A lesion involving the left CN VII would result in inability to close the left eye.

**(Choice D)** Inward deviation of the left eye would result from a CN VI lesion and the resultant unopposed action of CN III.

**(Choice E)** The left CN II is functional as it was able to produce a consensual response in the right eye.

**Educational objective:**
The pupillary light reflex is assessed by shining light in an eye and observing the response in that eye (direct) and the opposite eye (consensual). The optic nerve (CN II) is responsible for the afferent limb of the pupillary reflex, and the oculomotor nerve (CN III) is responsible for the efferent limb.

| Anatomy | Ophthalmology | Cranial nerve palsy |
|---|---|---|
| Subject | System | Topic |

A 15-year-old boy comes to the office due to right ear itching and discomfort for the past several days. He has no fever or hearing loss but has noted scant drainage of thin, whitish fluid. The patient has been taking swimming lessons at a local gym. On examination, there is no redness around the ear, but gentle traction of the pinna elicits pain. During inspection of the external auditory canal, a speculum is inserted into the meatus in close contact with its posterior wall, causing the patient to suddenly become lightheaded and faint. He recovers spontaneously within a few minutes with no residual confusion. Which of the following nerves was most likely irritated during the procedure?

A. Accessory
B. Facial
C. Trigeminal
D. Vagus
E. Vestibulocochlear

Submit

A 15-year-old boy comes to the office due to right ear itching and discomfort for the past several days. He has no fever or hearing loss but has noted scant drainage of thin, whitish fluid. The patient has been taking swimming lessons at a local gym. On examination, there is no redness around the ear, but gentle traction of the pinna elicits pain. During inspection of the external auditory canal, a speculum is inserted into the meatus in close contact with its posterior wall, causing the patient to suddenly become lightheaded and faint. He recovers spontaneously within a few minutes with no residual confusion. Which of the following nerves was most likely irritated during the procedure?

- A. Accessory (0%)
- B. Facial (10%)
- C. Trigeminal (6%)
- ✓ D. Vagus (50%)
- E. Vestibulocochlear (32%)

Omitted
Correct answer
D

50%
Answered correctly

02 secs
Time Spent

05/31/2020
Last Updated

Explanation

**Cutaneous innervation of the ear**

1
2
3
4
5
6
7
8
9
10
11
12
13
14
15
16
17

## Cutaneous innervation of the ear

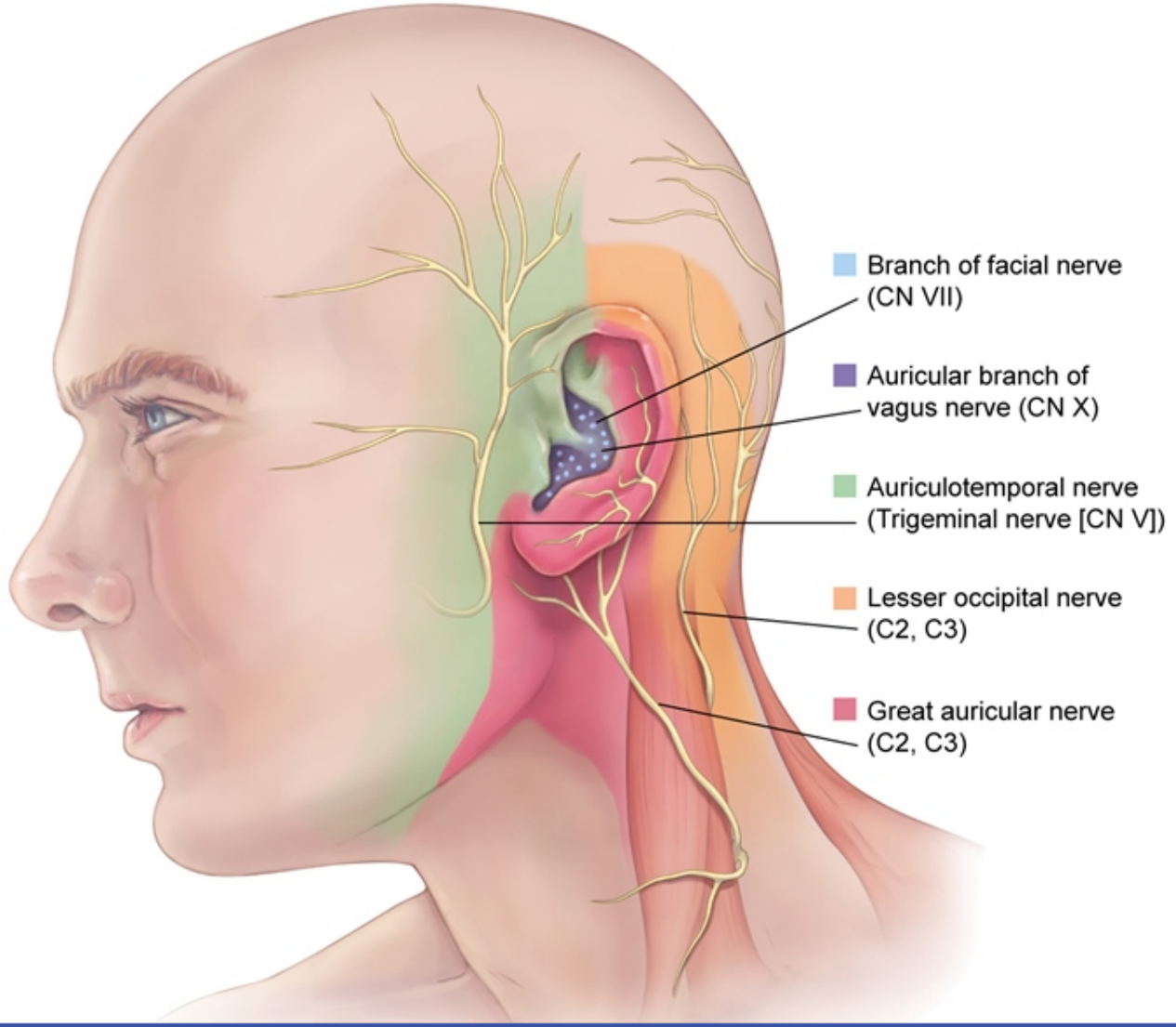

The majority of the external ear receives cutaneous innervation from the great auricular nerve, lesser occipital nerve, and auriculotemporal nerve. Most of the external auditory canal, including the external portion of the tympanic membrane, is innervated by the mandibular division of the trigeminal nerve (cranial nerve [CN] V3) via its auriculotemporal branch.

However, the **posterior** part of the **external auditory canal**, as well as the concavity and posterior eminentia of the concha, is innervated by the small auricular branch of the **vagus nerve** (CN X). This patient has experienced **vasovagal syncope** after stimulation of his posterior external auditory canal by an otoscope speculum. In this form of syncope, parasympathetic outflow via the vagus nerve leads to decreased heart rate and blood pressure.

**(Choice A)** The accessory nerve (CN XI) provides voluntary motor innervation to the trapezius and the sternocleidomastoid.

**(Choice B)** The facial nerve (CN VII) has a small motor component to the stapedius and muscles behind the ear. It supplies cutaneous sensation to a small area of the auricle, but stimulation here would be unlikely to trigger a vasovagal response.

**(Choice C)** The mandibular branch of the trigeminal nerve carries sensation from the majority of the external auditory meatus, except for the posterior wall.

**(Choice E)** The vestibulocochlear nerve (CN VIII) mediates hearing and vestibular proprioception. It does not mediate any cutaneous sensation.

**Educational objective:**
The vagus nerve provides cutaneous sensation to the posterior external auditory canal via its small auricular branch. Sensation to the rest of the canal is from the mandibular division of the trigeminal nerve.

| Anatomy | Ear, Nose & Throat (ENT) | Otitis externa |
|---|---|---|
| Subject | System | Topic |

Copyright © UWorld. All rights reserved.

A 36-year-old man is rushed to the emergency department after sudden onset of shortness of breath and difficulty swallowing. He has visited the emergency department several times before due to food and skin allergies. The patient is unconscious on arrival. Examination shows excessive accessory respiratory muscle use and edematous swelling of the face, lips, and tongue. There is also scattered urticaria over the upper body. Attempts at intubation are unsuccessful due to massive soft tissue edema involving the pharynx. A decision is made to perform an emergency cricothyrotomy. The incisions made during this procedure will most likely pass through which of the following structures?

A. Buccopharyngeal fascia and platysma

B. Platysma and thyroid isthmus

C. Pretracheal fascia and cricoid cartilage

D. Pretracheal fascia and prevertebral fascia

E. Superficial cervical fascia and cricothyroid membrane

Submit

A 36-year-old man is rushed to the emergency department after sudden onset of shortness of breath and difficulty swallowing. He has visited the emergency department several times before due to food and skin allergies. The patient is unconscious on arrival. Examination shows excessive accessory respiratory muscle use and edematous swelling of the face, lips, and tongue. There is also scattered urticaria over the upper body. Attempts at intubation are unsuccessful due to massive soft tissue edema involving the pharynx. A decision is made to perform an emergency cricothyrotomy. The incisions made during this procedure will most likely pass through which of the following structures?

A. Buccopharyngeal fascia and platysma (1%)

B. Platysma and thyroid isthmus (3%)

C. Pretracheal fascia and cricoid cartilage (29%)

D. Pretracheal fascia and prevertebral fascia (1%)

✓ E. Superficial cervical fascia and cricothyroid membrane (63%)

Omitted
Correct answer
E

63%
Answered correctly

02 secs
Time Spent

03/23/2020
Last Updated

Explanation

## Cricothyrotomy

## Cricothyrotomy

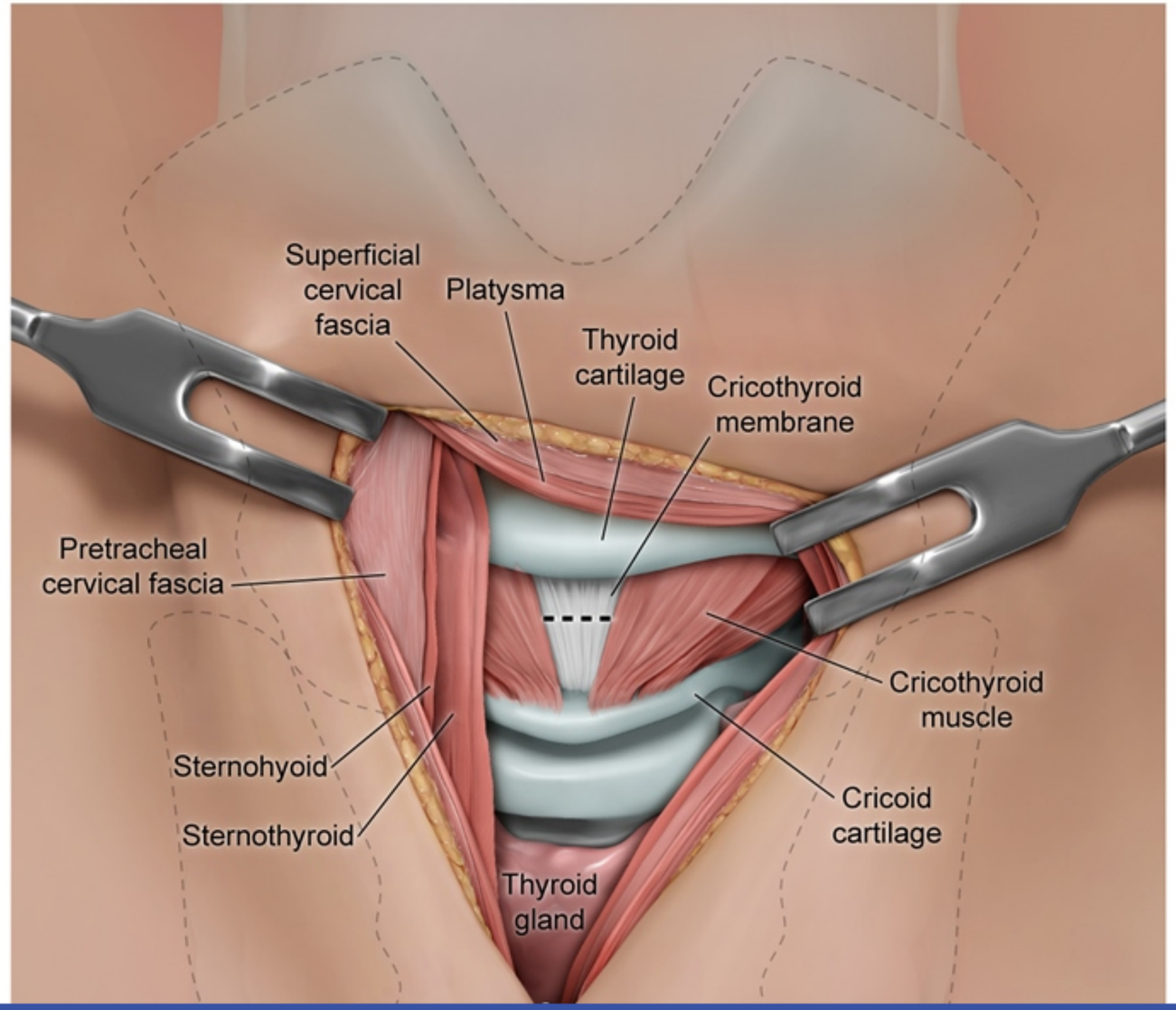

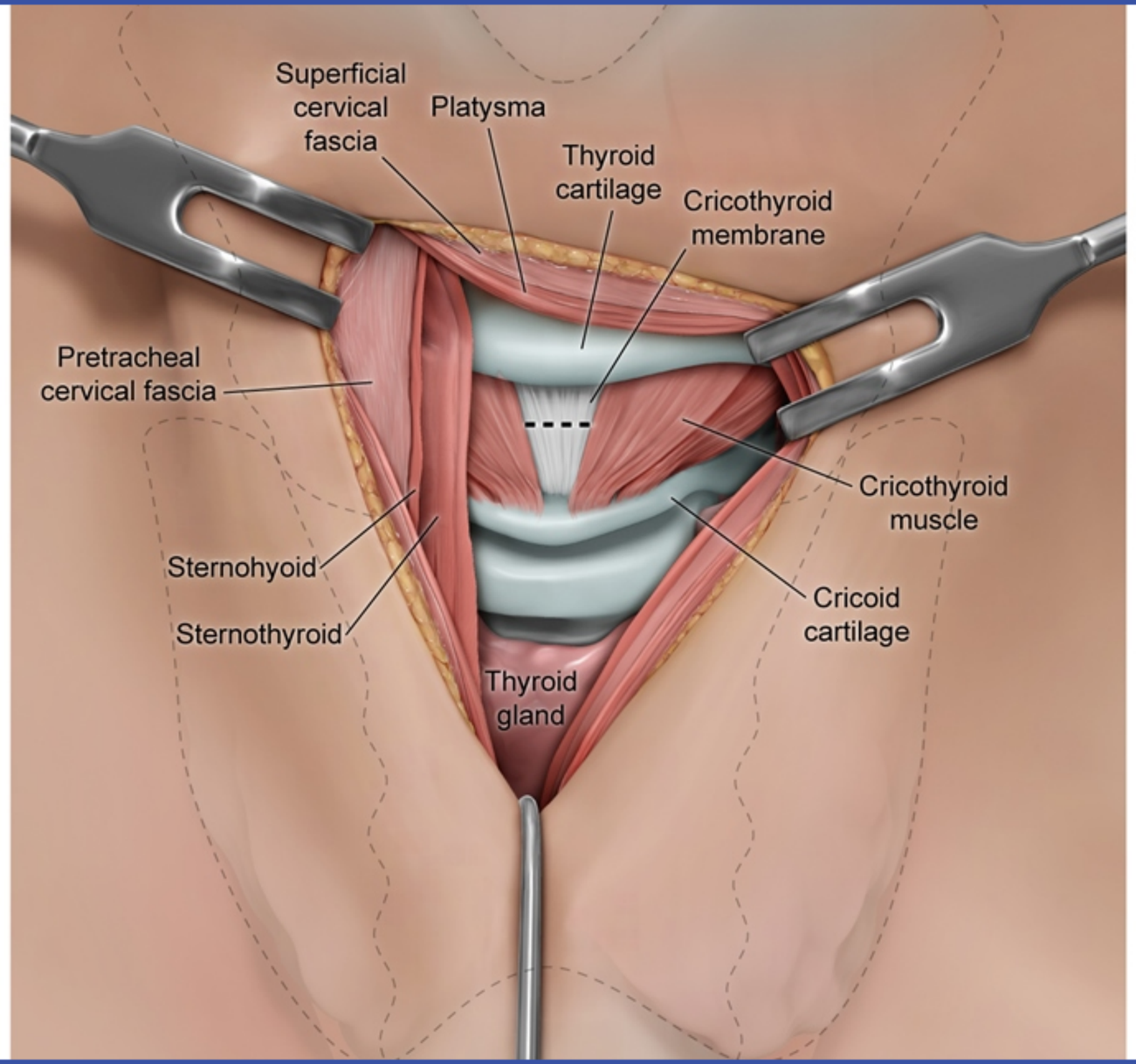
Superficial cervical fascia
Platysma
Thyroid cartilage
Cricothyroid membrane
Pretracheal cervical fascia
Cricothyroid muscle
Sternohyoid
Sternothyroid
Cricoid cartilage
Thyroid gland

©UWorld

This patient is experiencing acute, life-threatening laryngeal edema as part of an **anaphylactic reaction** precipitated by exposure to an allergen. **Laryngeal edema** can initially present with throat tightness, difficulty swallowing, dyspnea, and hoarseness. However, the condition can **quickly progress** to compromise the airway and cause **asphyxiation**.

**Cricothyrotomy** is indicated when an emergency airway is required and orotracheal or nasotracheal intubation is either unsuccessful or contraindicated (eg, massive hemorrhage, vomiting, facial trauma, airway obstruction). The procedure establishes an airway through the placement of a tube between the cricoid and thyroid cartilages and requires incision through the following structures:

1. Skin
2. **Superficial cervical fascia** (including subcutaneous fat and **platysma** muscle)
3. Investing and pretracheal layers of the deep cervical fascia
4. **Cricothyroid membrane**

**(Choice A)** The buccopharyngeal fascia invests the pharyngeal constrictor muscles and lies anterior to the alar fascia, forming the retropharyngeal space between them. The danger space lies posterior to the retropharyngeal space (between the alar and prevertebral fascia). Retropharyngeal abscesses can drain directly into the superior mediastinum or penetrate into the danger space to extend along the entire length of the mediastinum, causing acute necrotizing mediastinitis.

**(Choices B and C)** The cricoid cartilage lies inferior to the thyroid cartilage at the level of the C6 vertebra, and the thyroid isthmus lies inferior to the cricoid cartilage. Incisions made during cricothyrotomy should be performed with care to prevent damage to these structures.

**(Choice D)** The deep cervical fascia is composed of three layers: investing, pretracheal, and prevertebral. The prevertebral layer of the deep fascia surrounds the vertebral column and spinal muscles; it is not penetrated during cricothyrotomy.

**Educational objective:**
Cricothyrotomy is indicated when an emergency airway is required and orotracheal or nasotracheal intubation is either unsuccessful or contraindicated. The cricothyrotomy incision passes through the superficial cervical fascia, pretracheal fascia, and the cricothyroid membrane.

| Anatomy | Ear, Nose & Throat (ENT) | Airway emergency |
|---|---|---|
| Subject | System | Topic |

**Laryngeal edema** can initially present with throat tightness, difficulty swallowing, dyspnea, and hoarseness. However, the condition can **quickly progress** to compromise the airway and cause **asphyxiation**.

**Cricothyrotomy** is indicated when an emergency airway is required and orotracheal or nasotracheal intubation is either unsuccessful or contraindicated (eg, massive hemorrhage, vomiting, facial trauma, airway obstruction). The procedure establishes an airway through the placement of a tube between the cricoid and thyroid cartilages and requires incision through the following structures:

1. Skin
2. **Superficial cervical fascia** (including subcutaneous fat and **platysma** muscle)
3. Investing and pretracheal layers of the deep cervical fascia
4. **Cricothyroid membrane**

**(Choice A)** The buccopharyngeal fascia invests the pharyngeal constrictor muscles and lies anterior to the alar fascia, forming the retropharyngeal space between them. The danger space lies posterior to the retropharyngeal space (between the alar and prevertebral fascia). Retropharyngeal abscesses can drain directly into the superior mediastinum or penetrate into the danger space to extend along the entire length of the mediastinum, causing acute necrotizing mediastinitis.

**(Choices B and C)** The cricoid cartilage lies inferior to the thyroid cartilage at the level of the C6 vertebra, and the thyroid isthmus lies inferior to the cricoid cartilage. Incisions made during cricothyrotomy should be performed with care to prevent damage to these structures.

**(Choice D)** The deep cervical fascia is composed of three layers: investing, pretracheal, and prevertebral. The prevertebral layer of the deep fascia surrounds the vertebral column and spinal muscles; it is not penetrated during cricothyrotomy.

**Educational objective:**
Cricothyrotomy is indicated when an emergency airway is required and orotracheal or nasotracheal intubation is either unsuccessful or contraindicated. The cricothyrotomy incision passes through the superficial cervical fascia, pretracheal fascia, and the cricothyroid membrane.

| Anatomy | Ear, Nose & Throat (ENT) | Airway emergency |
|---|---|---|
| Subject | System | Topic |

Copyright © UWorld. All rights reserved.

**Laryngeal edema** can initially present with throat tightness, difficulty swallowing, dyspnea, and hoarseness. However, the condition can **quickly**

Exhibit Display

**Deep neck space anatomy**

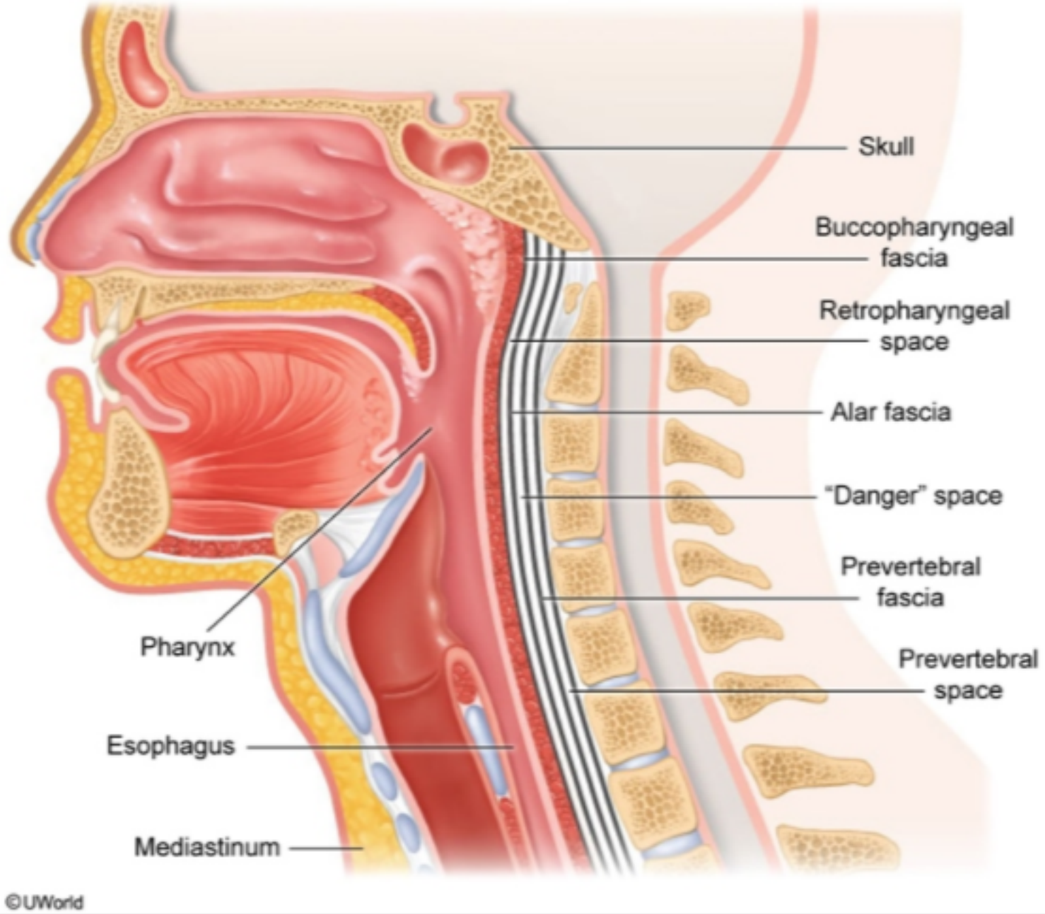


Zoom In | Zoom Out | Reset | Add To New Card | Existing Card

**Laryngeal edema** can initially present with throat tightness, difficulty swallowing, dyspnea, and hoarseness. However, the condition can **quickly**

**Exhibit Display**

Zoom In | Zoom Out | Reset | Add To New Card | Existing Card

**Laryngeal edema** can initially present with throat tightness, difficulty swallowing, dyspnea, and hoarseness. However, the condition can **quickly**

Exhibit Display

## Fascia of the neck

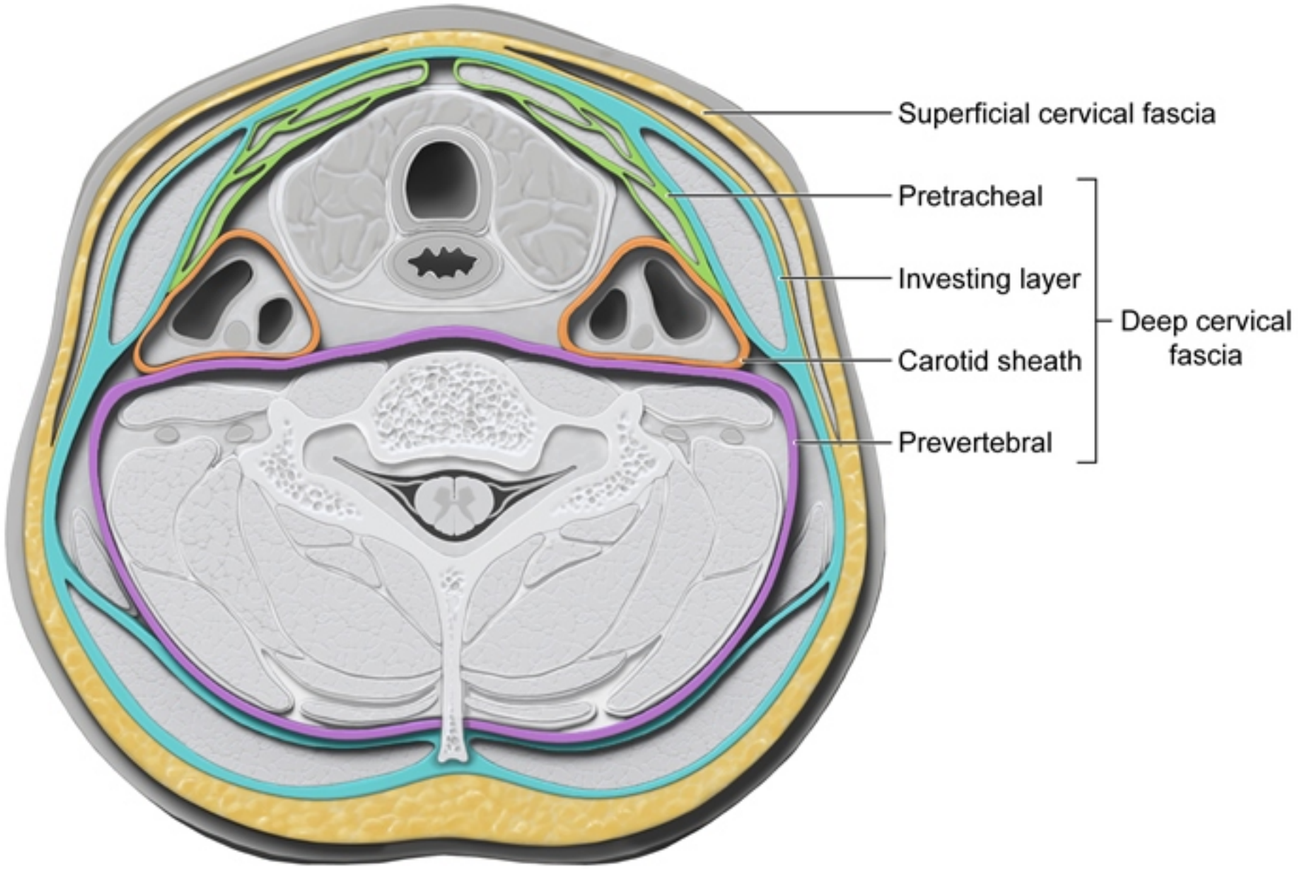


©UWorld

Zoom In | Zoom Out | Reset | Add To New Card | Existing Card

A 50-year-old man comes to the office due to a lump in his neck that has been present for 4 months and is enlarging. On examination, there is a firm, nontender, nonmobile mass in the right anterior neck. Otoscopic examination shows a clear right middle ear effusion. Needle biopsy of the neck mass is consistent with regional nodal spread of squamous cell carcinoma. Which of the following is the most likely site of the primary tumor?

A. Base of tongue
B. Nasopharynx
C. Parotid gland
D. Piriform sinus
E. Thyroid gland
F. Vocal cord

Submit

A 50-year-old man comes to the office due to a lump in his neck that has been present for 4 months and is enlarging. On examination, there is a firm, nontender, nonmobile mass in the right anterior neck. Otoscopic examination shows a clear right middle ear effusion. Needle biopsy of the neck mass is consistent with regional nodal spread of squamous cell carcinoma. Which of the following is the most likely site of the primary tumor?

- A. Base of tongue (23%)
- ✓ B. Nasopharynx (40%)
- C. Parotid gland (8%)
- D. Piriform sinus (3%)
- E. Thyroid gland (6%)
- F. Vocal cord (18%)

Omitted
Correct answer
B

40%
Answered correctly

02 secs
Time Spent

02/27/2020
Last Updated

Explanation

**Squamous cell carcinoma** that originates in the mucosa of the head and neck typically spreads first to the **anterior cervical lymph nodes**. An enlarged, firm cervical lymph node is often the presenting symptom of head and neck squamous cell carcinoma (HNSCC). Identification of the primary site of tumor formation is important for staging and to guide treatment strategies.

This patient's **unilateral middle ear effusion** suggests **obstruction** of the **eustachian tube**, which connects the middle ear space to the nasopharynx. It opens intermittently, typically during swallowing or yawning to equalize pressure in the middle ear. Failure to adequately open

**Squamous cell carcinoma** that originates in the mucosa of the head and neck typically spreads first to the **anterior cervical lymph nodes**. An enlarged, firm cervical lymph node is often the presenting symptom of head and neck squamous cell carcinoma (HNSCC). Identification of the primary site of tumor formation is important for staging and to guide treatment strategies.

This patient's **unilateral middle ear effusion** suggests **obstruction** of the **eustachian tube**, which connects the middle ear space to the nasopharynx. It opens intermittently, typically during swallowing or yawning to equalize pressure in the middle ear. Failure to adequately open causes negative pressure to build within the middle ear, leading to a transudative effusion (clear, amber, or yellow). Eustachian tube dysfunction can be due to anatomic obstruction from a **mass in the nasopharynx** or, more commonly, due to functional obstruction from infections, allergic rhinitis, or irritants (eg, tobacco smoke).

**(Choices A, D, and F)** HNSCC can originate from the mucosa of other anatomic sites. Many sites (eg, base of tongue, piriform sinus) initially cause only vague or minor symptoms, but some may present with more specific features (eg, hoarseness in vocal cord cancer). Cancer at any of these other sites (ie, base of tongue, piriform sinus, vocal cord) would not lead to obstruction of the eustachian tube with a resultant middle ear effusion.

**(Choice C)** Cancer of the parotid gland may spread to the cervical lymph nodes. The superior portion of the parotid gland is near the external auditory canal of the ear, not the eustachian tube. In addition, because the parotid gland is near the skin surface, primary tumors of the parotid are typically palpable.

**(Choice E)** Cancer of the thyroid gland may spread to the cervical lymph nodes. However, it is very rare to have squamous cell carcinoma in the thyroid, and enlargement of the thyroid gland would not block the eustachian tube.

**Educational objective:**
The eustachian tube connects the middle ear to the nasopharynx. Cancer located in the nasopharynx can lead to obstruction of the eustachian tube, causing a middle ear effusion.

| Anatomy | Ear, Nose & Throat (ENT) | Head and neck cancers |
|---|---|---|
| Subject | System | Topic |

Copyright © UWorld. All rights reserved.